

Research Article

Open Access

Protective Effects of Quercetin/Moss Extract (*Homalothecium Sericeum* Hedw.) Combination on STZ-Induced Diabetic Rats

Ozlem Tonguc Yayintas^{1*}, Samil Ozturk², Latife Ceyda Irkin³ and Nesrin Demir⁴

¹Canakkale Onsekiz Mart University, Faculty of Medicine, Department of Medical Biology, Canakkale-Turkey

²Canakkale Onsekiz Mart University, Vocational School of Health Services, Canakkale-Turkey

³Canakkale Onsekiz Mart University, School of Applied Sciences, Department of Fisheries Technology Canakkale-Turkey

⁴Antalya Bilim University, Faculty of Dentistry, Antalya – Turkey

ABSTRACT

Diabetes Mellitus (DM) is the most common chronic endocrine disorder. Although new drugs and administration techniques for diabetes were developed, the nature of complications that occur chronically and reduce patients' quality of life have not been entirely determined. In our study, 35 male rats were used. A single dose of 40 mg/kg streptozotocin was injected intraperitoneal into 28 rats, and a total of five groups were formed. The diabetes model was performed by applying 40mg/kg STZ and was not established in the subjects in the control and citrate buffer groups with STZ solvent. The quercetin and moss extract were given by gavage for three weeks. The liver and pancreas tissues were examined by histochemical and immunohistochemical methods. Ki-67 (proliferation marker), antinuclear factor kappa (NF-κB), and interleukin 6 (IL-6) immunohistochemically staining revealed significant differences in inflammation and regeneration in the liver and pancreas tissues. In addition, the TUNEL staining method was used to determine apoptosis. Positivity was significant between the treatment and diabetes groups. It was determined that the agents used as treatment changed serum superoxide dismutase (SOD), malondialdehyde (MDA), C-peptide, insulin, and glucose levels.

*Corresponding author

Ozlem Tonguc Yayintas, Canakkale Onsekiz Mart University, Faculty of Medicine, Department of Medical Biology, Canakkale-TURKEY.
Email: ozlemyayintas@hotmail.com

Received: December 21, 2022; **Accepted:** December 27, 2022; **Published:** December 30, 2022

Keywords: Diabetes Mellitus, Apoptosis, Bryophytes, Immunohistochemistry, Quercetin

Introduction

Type 2 diabetes is a metabolic disease in which hyperglycemia occurs due to the deterioration of secretion of the insulin hormone and the effect of insulin [1]. Due to diabetes being a chronic disease, high health care costs, and side effects of the drugs used, the interest in alternative or supportive/complementary treatments has increased. Nowadays, it is noteworthy that diabetic patients use antihyperglycemic drugs (such as insulin, and metformin) and herbal drugs with high antioxidant and antihyperglycemic properties to fight against hyperglycemia [2].

Many studies suggest that individuals who develop DM display features of inflammation several years before DM is diagnosed [3]. Increasing evidence indicates that activation of the innate immune system and the presence of low-grade inflammatory chronic subclinical conditions are widely associated with the pathogenesis of diabetes mellitus [4, 5]. In addition, inflammatory cytokines were implicated in the pathogenesis of microvascular diabetic complications [6, 7]. Population-based studies showed that various inflammatory markers, such as cytokines, are strong

predictors of diabetes development [8, 9]. NFκB is a transcription factor that controls the expression of genes involved in different processes such as immune response, cell differentiation and development, apoptosis, inflammation, and tumorigenesis. NFκB regulates many target genes, including adhesion molecules, chemokines, inflammatory cytokines, nitric oxide synthase, and all other molecules involved in inflammation and proliferation [10].

As reported in diabetes, hyperglycemia may interfere with the antioxidant defense system by causing changes in the activities of antioxidant enzymes. Changes in the antioxidant defense system in the diabetic state in diabetic animal models were documented as a significant reduction in SOD activity in red blood cells [11]. In addition, oxidative stress was reported to be a known pathway in the pathogenesis of diabetic complications [12]. To evaluate the impact of oxidative stress on type 2 diabetes mellitus, a study was conducted including 309 diabetic individuals at the Diabetic Clinic of Charles Sturt University in Australia. The non-diabetic control group was normoglycemic, normotensive, and had no history or evidence of cardiovascular disease. The researchers collected blood and urine samples and measured blood sugar, lipids, and oxidative stress biomarkers. There were significant increases in glycosylated hemoglobin, lipids, and oxidative stress

biomarker levels in the diabetic group compared to non-diabetics. The findings support the association between type 2 diabetes and hyperglycemia-induced oxidative stress, chronic hyperglycemia, and type 2 diabetes progression [13].

Quercetin is a common dietary flavonoid found in many vegetables and fruits, including onions, lettuce, tomatoes, hot peppers, broccoli, apples, and strawberries [14]. Specifically, quercetin is one of the most potent natural antioxidants with various pharmacological effects, including anti-inflammatory, anti-allergic, anti-ulcer, anti-cancer, cardio protective, neuroprotective, and anti-atherogenic activities [15]. In addition, quercetin was reported to have antidiabetic potential in several preclinical studies [16]. Therefore, the inclusion of quercetin as a natural treatment product to prevent diabetes and its complications has gained considerable attention [17, 18]. In a study administering quercetin to male rats with experimental diabetes mellitus induced with STZ, quercetin played a stabilizing role in blood sugar control [19]. In another study examining the effect of quercetin on protein and lipid damage in experimental diabetic rats, quercetin did not have a practical protective feature against protein damage caused by DM but had a protective role against lipid peroxidation. In a study administering quercetin to rats, it prevented the formation of free oxygen radicals in cells and provided protection against lipid peroxidation [20]. In addition to studies that reporting that quercetin administration inhibited lipid peroxidation, there are also studies reporting it reduced lipid peroxidation in human lymphocytes [21].

Mosses are the oldest land plants used to treat many diseases in alternative medicine for more than 400 years. The antioxidant activities of mosses, which have physiological importance, are high. The presence of antioxidant activity in mosses and the search for natural antioxidants in research has increased interest in mosses. Maytansinoid, an antitumor agent, and its derivatives were isolated from the actinomycete, *Actinosynnema pretiosum*, mosses, and higher plants. Many of these compounds are antitumor agents with extraordinary potency and include maytansinoids as "warheads" in tumour-specific antibodies. Among the 219 moss extracts tested, 41 extracts encouraging cell division were identified to have various combinations of significant effects on interphasic and mitotic cells. Seven sections were further studied using cell viability assays, cell cycle analysis, and phenotype determination assay. Three different pharmacological patterns were identified, including two unusual phenotypes [22, 23].

Active compounds responsible for the antimicrobial effects present in many bryophyte species have been identified. For example, some liverwort extracts such as polygodial from *Porella*, polygodial from *Conocephalum conicum*, and lunularin from *Lunularia cruciata* are not only effective fungicides and bactericides but also have weak biocidal (stomach poison) effects against harmful insects [24]. Alcoholic or acidic extracts of *Polytrichum juniperinum* were found to exert antitumor activity against carcinoma when injected into muscle cells of CAF1 mice [25]. In other cases, bryophyte extracts had tumor-promoting activity. Asakawa found that molecules such as marchantin A, cyclopentenyl fatty acids, and their precursors had antimicrobial activity. Sanionin A and B were isolated from *Sanionia uncinata* collected from Livingston Island in the Antarctic [26]. These compounds showed inhibitory activity against multiresistant staphylococci, gram-positive pathogens, and vancomycin-resistant enterococci. Anti-inflammatory activity and low cytotoxicity were also observed [27].

The findings of moss studies show that their antibacterial and anti-cancer properties are high due to the flavonoid content. Experimentally, in vivo studies seem to be very limited. The species we studied has never been used in experimental animal models in the literature. In this respect, the results of the study will contribute to the literature. In future studies, molecular techniques will contribute to the use of moss extracts in medical treatments with more specific findings. Especially considering its anti-cancer properties, prodrugs with low cost and short duration can be developed for cancer treatments increasing day by day.

In light of this information, we aimed to investigate the effects of moss (*Homalothecium sericeum* Hedw.) (HS), which we observed before, and quercetin, which was proven to have significant antioxidant properties, to eliminate the complications caused by diabetes. Therefore, the aim was to carry out innovative and pioneering studies that will contribute to the scientific world to minimize diabetes-related problems in the future in individuals who develop diabetes at a young age and have congenital diabetes.

Materials and Methods

Homalothecium sericeum belongs to the Bryophyta division, Bryopsida class, Hypnales order, Brachytheciaceae family. It is one of the five taxa of the genus *Homalothecium* in our country [28]. *Homalothecium sericeum* is a taxon that loves bare and arid environments and open areas, spreading epiphytically on tree trunks and in epilithic environments such as stone, wall, and rock surfaces [29]. Research material was collected from Kazdağları (Çanakkale, Turkey). The mosses cleaned of foreign materials were left to dry in the natural environment and the dried samples were ground into powder. The material in the form of flour was treated with methanol at a rate of 10 ml/g for 24 hours in the dark, and the extraction process was carried out in capped flasks at room temperature and with shaking. The moss sample was treated with methanol until the extract became colorless, was filtered through filter paper, and given to the rat groups at doses of 150 mg/kg. Consent was obtained from the Experimental Animals Ethics Committee.

Approximately 6–8-week-old Wistar albino rats weighing 200–300 g and 35 male rats were used in the study. A single dose of 40 mg/kg streptozotocin was injected into 28 rats by IP route. Before streptozotocin injection, blood glucose levels were checked, and applying STZ; glucose measurements were made in the blood taken from the tail vein of the subjects. Post-STZ blood glucose values were determined with a glucometer. Optima brand rapid glucometer was used. One day after the infusion, fasting blood glucose value was measured in blood taken from the tail vein following a fasting period of 8–10 hours. Blood glucose values were started 24 hours after STZ administration, and measurements were repeated for five days. Rats that developed hyperglycemia were included in the treatment groups, considering the averages. Glucose values exceeding 250 mg/dl were considered diabetic.

Experimental Groups

Experimental groups were determined in 5 different ways:

1. Control (C) (n=7): A single dose of 1 cc of citrate buffer injected intraperitoneally.
2. Diabetes (D) (n=7): A single dose of 40 mg/kg streptozotocin dissolved in citrate buffer (0.01M, pH=4.5) was administered to the subjects.
3. Diabetes + Moss (DHS) (n=7): After diabetes was established, 150 mg/kg of moss extract prepared for treatment was given to the subjects by the gavage method for three weeks.

4. Diabetes + Quercetin (DQ) (n=7): Sigma-Aldrich (Q4951) brand Quercetin was used and 2 ml of the aqueous solution was prepared. After diabetes was established, 50 mg/kg of quercetin prepared for treatment was given to the subjects by the gavage method for three weeks.
5. Diabetes + Moss + Quercetin (DHSQ) (n=7): Moss extract 150 mg/kg + quercetin 50 mg/kg dose prepared for treatment was given to the subjects by the gavage method for three weeks.

Blood Glucose Measurement

Before starting the experiment, each rat's blood glucose was measured. Seventy-two hours after STZ administration, rat blood glucose levels were measured from the tail vein with a glucometer.

Method

The animal model study in our research continued for one month. At the end of the period, liver and pancreas tissues of rats anaesthetized with rompun %2 (Bayer, 10mg/kg, i.p) and ketamine HCL (Bionchepharm, 70 mg/kg i.p) were taken, trimmed, placed in tissue transport cassettes, and fixed in immunofix for 24 hours. The tissue samples were purified of water in the tissue by passing them through graded alcohol solutions, respectively; the alcohol in the tissues was cleaned with xylene, and the tissue samples were blocked in a base mold after they were kept in paraffin in the oven. Blocked tissue samples were cut to 3-5 microns thick with a microtome, placed on slides, and put in preparation boxes. Routine histochemical staining and immunohistochemical staining were performed on tissue samples taken from each subject and cut to 5-micron thickness.

Immunohistochemically Staining

Tissue samples were cut with a microtome to a thickness of 5 microns and placed in a water bath. The tissue samples were placed on unique slides covered with Poly L-Lysine (Thermo Scientific) and kept on a heating plate (Leica) at 40 °C for 1 hour to ensure adhesion. Serum blocking solution was used for tissue samples that were allocated as a negative control, polyclonal rabbit anti-nuclear factor-kappa B (NFκB p65, Abcam (ab16502) and interleukin-6 (IL-6 ab6672), Ki-67 (ab231172) were used as primary antibodies for other tissue samples. This procedure was applied separately for each antibody. It was diluted 1/50 with distilled water. The dilution of primary antibodies was made with antibody diluent reagent (Invitrogen) solution. Tissue samples on which NFκB, IL-6, and Ki-67 were added were incubated for 1 hour in a 37°C oven. After the primary antibodies were poured on the tissue samples, each tissue sample was washed one by one with PBS three times for 3 minutes. After cleaning, the remaining PBS solution around each piece was removed with blotting paper, and biotinylated secondary antibody solution (LAB-SA Detection System, Histostain-Plus Bulk Kit; A solution, Invitrogen) was placed on the samples and left for 30 minutes. After the tissue samples were placed in deionized water two times and for 2 minutes, they were kept in Mayer's hematoxylin for 5 minutes for counterstaining and washed in tap water for 10 minutes. Then, samples were passed through xylene and graded alcohols and covered with a coverslip using entellan (Bio Mount, Bio-Optica) [30].

Tunel Assay

In determining cell death, the Terminal Transferase dUTP Nick End Labeling (TUNEL, ApopTag® Plus Peroxidase in Situ Apoptosis Kit) method allowing staining of apoptotic cells was used. After the deparaffinization process, the sections were washed first in distilled water and then with PBS solution for 3x5 minutes. Then, 20-μg/ml Proteinase-K diluted to 1/500 with PBS solution was applied for 15 minutes at room temperature. After washing with PBS, they were treated with 3% H₂O₂ for 5 minutes, then washed again with PBS for 3x5 minutes. The samples were kept at room temperature with equilibration buffer for 5 minutes and then kept in a humid environment at 37 °C with TdT-enzyme for 1 hour. Next, samples were treated with Stop Wash Buffer for 10 minutes and then with Antidioxigenin Peroxidase Conjugate for 30 minutes and washed with PBS for 3x5 minutes. Then dyeing was done with DAB, and background staining was done with Mayer's hematoxylin. TUNEL positive cells were detected by the blind method, and the averages were evaluated statistically [30].

Evaluation of Tissue Samples and Statistics

All stained tissue samples were evaluated under a Zeiss AXIO Scope 1 brand research microscope and photographed with a digital camera (Axio Cam ICc 3). NFκB, IL-6, and Ki-67 immunoreactive cells were detected using the Leica LAS V3.8 image analysis system. Five of the sections taken from blocks containing liver tissue of rats in all groups were stained, and immunoreactive cells were determined among these cells by counting 1000 cells on the stained sections.

immune positive cells

----- X 100% = ... %

Total number of cells (1000)

SPSS 19 version was used for statistical evaluation of the results obtained with this formula. The Kruskal-Wallis Test, one of the non-parametric tests, was used to determine the immunoreactivity differences between the groups, and the difference between the groups was considered significant when $p < 0.05$.

Results

Blood Glucose Levels

Before and after the STZ administration to all subjects, blood glucose values were measured with a glucometer. The subjects belonging to the groups were given moss and quercetin for control, diabetes, and therapeutic purposes. When the blood glucose levels were evaluated, the blood glucose level of all groups was approximately 100 mg/dl at the beginning. There was no statistically significant difference in the blood glucose level of the control group from the beginning to the end of the experiment. However, the blood glucose values of the experimental groups were significantly higher at the beginning of the experiment (2 days after STZ administration) than in the control group ($p < 0.0001$). After the DHS and DQ procedure, blood sugar was significant in the DHC group ($p < 0.05$), in the DQ group ($p < 0.01$), and in the DHCQ group ($p < 0.001$) compared to the diabetes group (Table 1). Biochemical parameters of insulin, glucose, MDA, SOD, triglyceride, and C-peptide were analyzed by an Elisa device using the relevant Elisa kits (Sigma Aldrich).

Table 1. Blood glucose values of control and experimental groups

Groups/Blood glucose value	C	D	DHS	DQ	DHSQ
Treatment/ Before	98±2.6	404±14.21	378±18.41	476±28.68	448±20.24
Treatment/After	101±3.1	469±11.14	264±16.54	225±15.30	211±12.24

Histopathology

In the histological staining performed with hematoxylin-eosin (H&E), no histopathological findings were found in the liver tissues of the rats in the control group. It was observed that the central vein and hepatocyte trailers forming the lobule were in the center of the classical liver lobule, as expected (Fig. 1a). Hepatocyte vacuolization characterized by intense non-alcoholic adiposity in the liver tissues, dilatations in the vena centralis and portal veins, infiltration of mononuclear cells in the liver parenchyma and around the portal areas, and increased congestion in the veins were observed in the group administered a single dose of STZ (40 mg/kg). Initially, a single dose of 40 mg/kg of STZ was administered to 28 rats. However, after 48 hours, hyperglycemia developed in 24 rats, and a second repeat dose was administered to 4 rats. It was also observed that the hepatocyte series leading to spotty type necrosis increased (Fig. 1b). In the subjects of the group given HS for treatment, the histopathological picture was similar to the diabetes group but with more moderate degeneration and decreased cell loss due to vacuolization (Fig. 1c). It was determined that hepatocyte vacuolization and necrotic areas decreased in the subjects in the Q-treated group (Fig. 1d). However, sinusoidal dilatation and congestion continued. It was observed that the degeneration of the liver tissues considerably reduced in the group given Q+HS, and the histopathological picture progressed in the regenerative direction (Fig. 1e).

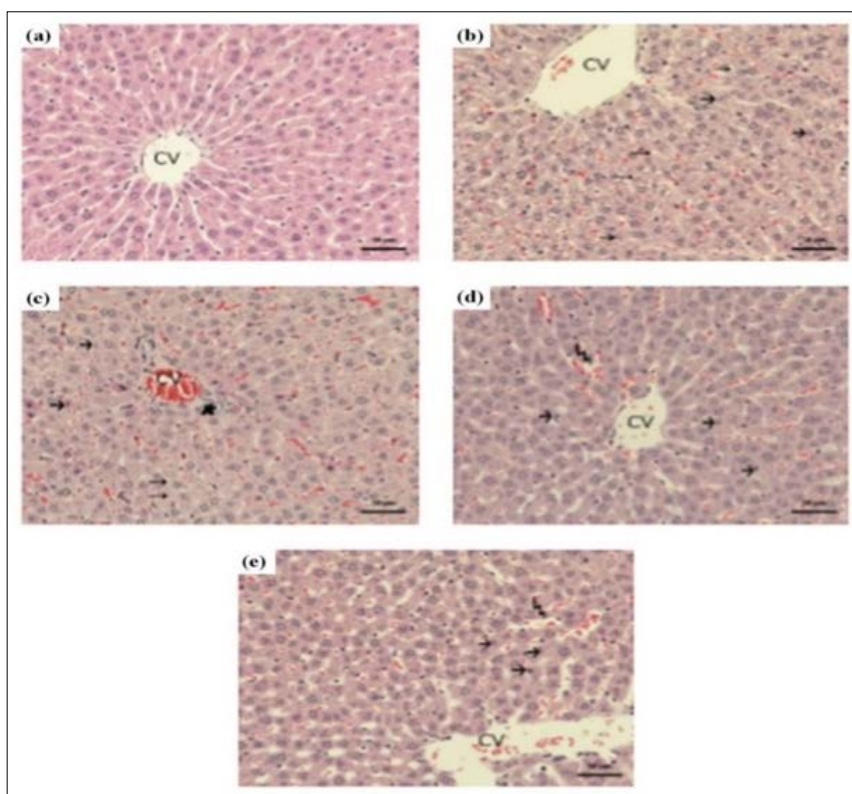


Figure 1: a Control, b STZ liver tissue, c Liver tissue with HS treatment, d Liver tissue with Q treatment, e Liver tissue with HS+Q treatment (CV: Central vein, long arrow: hepatocyte vacuolization, short arrow: hepatocytes with pycnotic nuclei, lightning: sinusoidal dilatation), H&E, X20

Immunohistochemical staining results using Ki-67, NFκB, and IL-6 antibodies were in parallel with the findings obtained for H&E staining. It was determined that NFκB and IL-6 immunoreactivity was quite severe in the diabetes group (Fig. 2b and Fig. 3b) and decreased in the treatment groups (Figs. 2c, d, e and Figs. 3c, d, e). Immunoreactivity had a mild course, especially in the group given Q+HS (Fig. 2e and Fig. 3e). A statistically significant difference was observed between the control and diabetes groups ($p < 0.0001$).

There was also a significant difference between the control group and those given moss and quercetin ($p < 0.05$). In addition, the intensity of immunoreactivity and the number of stained cells were less than inflammatory markers in Ki-67 immunohistochemical staining used to monitor regenerative activity (Fig. 4).

While reactivity was very low in the control group (Fig. 4a), regeneration in the liver was triggered due to the damage caused by oxidative stress in the diabetes group (Fig. 4b). It was observed that the number of Ki-67 positive cells increased.

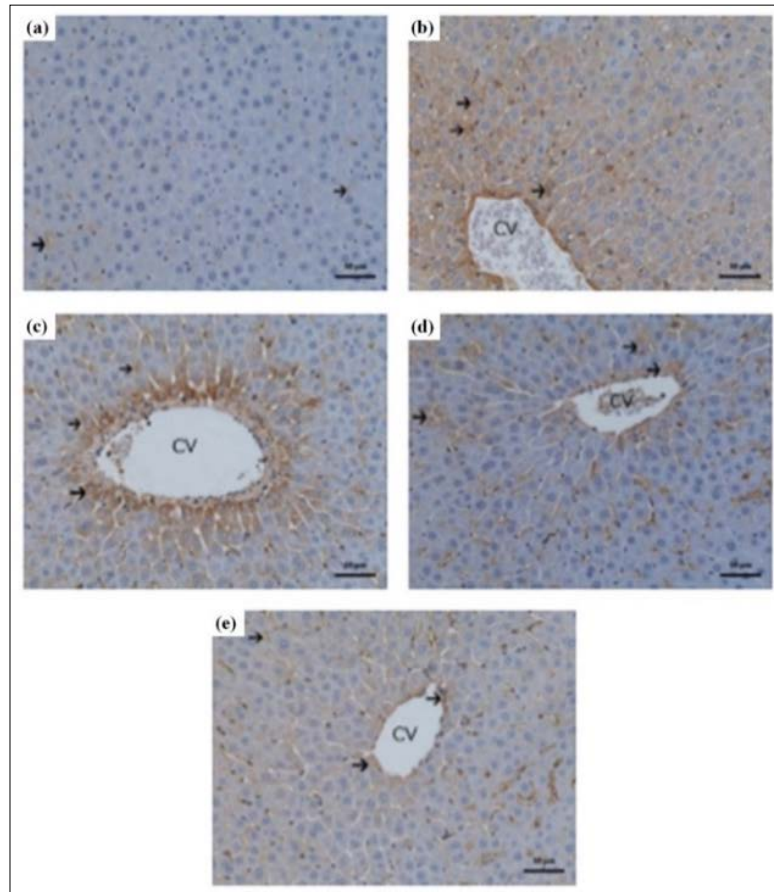


Figure 2: a Control, b Diabetes, c HS treatment, d Q treatment, e HS+Q treatment group liver tissue. NFκB immunohistochemical staining, X20 (Arrow: Immunoreactivity)

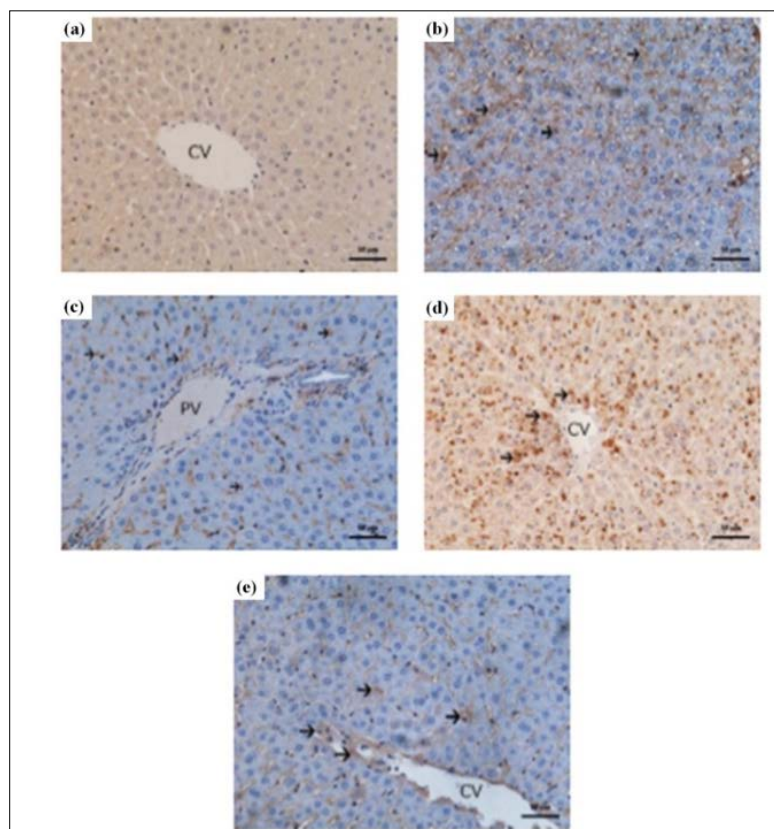


Figure 3: a Control, b Diabetes, c HS treatment, d Q treatment, e HS+Q treatment group liver tissue. IL-6 immunohistochemical staining, X20 (Arrow: Immunoreactivity)

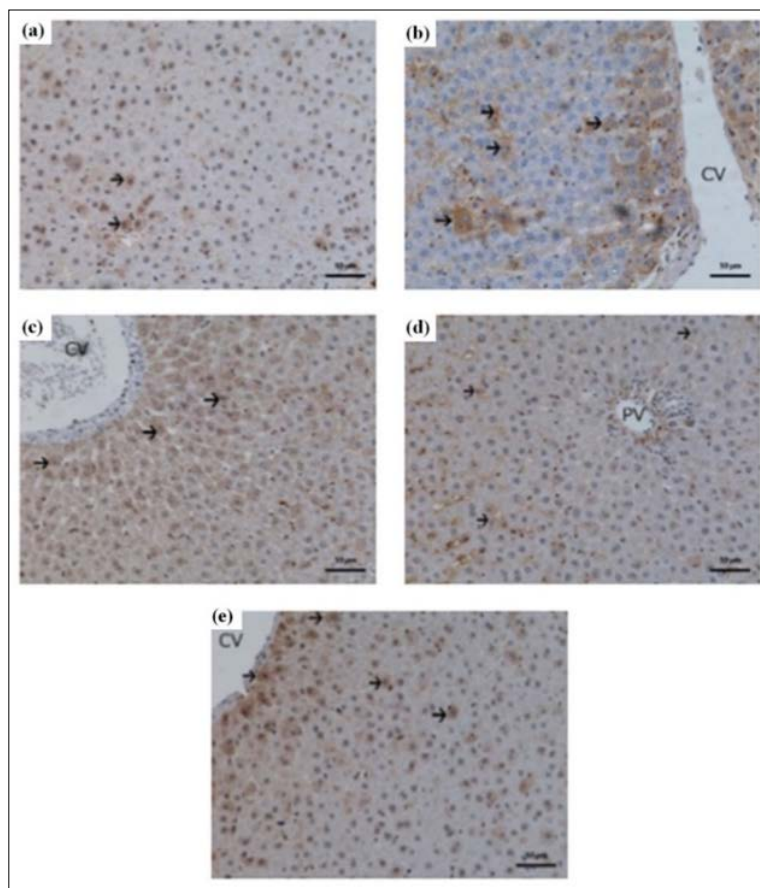


Figure 4: a Control, b Diabetes, c HS treatment, d Q treatment, e HS+Q treatment group liver tissue. Ki-67 immunohistochemical staining, X20 (Arrow: Immunoreactivity)

Tunnel Findings

While the mechanism of programmed cell death usually occurs in embryonic tissues, disruption of oxidant-antioxidant balance and degeneration in adult tissue are essential processes that trigger apoptosis. Hepatocellular damage, especially oxidative stress, and inflammation lead to apoptosis of hepatocytes with released cytokines. Disruption of functional operations in tissue is one of the vital triggers for apoptosis. With the release of TNF-alpha from Kupffer cells, the apoptotic mechanism is activated, and hepatocytes enter the apoptotic process. This event does not only result in cellular death. At the same time, conditions become favorable for new repairs. Thus, while the liver is destroyed by apoptosis, on the one hand, events that will create rapid regeneration occur on the other hand. While apoptotic activity did not occur in the control group (Fig. 5a), the increase in the number of cells progressing to apoptosis was relatively high in the diabetes group (Fig. 5b). The number of apoptotic cells decreased in the treatment groups (Figs. 5c and d). TUNEL positivity, which was used to mark apoptotic cells, was low especially in the HS+Q group (Fig. 5e). The number of TUNEL-positive cells in the groups given only moss and only quercetin was higher than in the group given both HS+Q. This means that administering HC (moss) extract with an agent with known antioxidant properties such as quercetin can prevent liver damage.

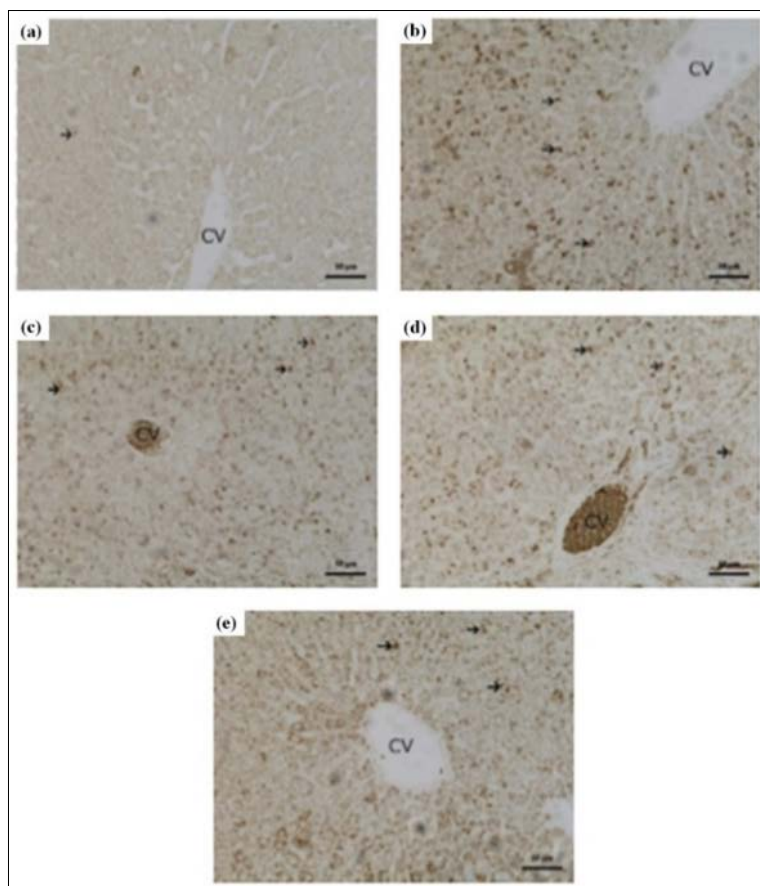


Figure 5 a Control group liver tissue TUNEL staining, b Diabetes group liver tissue, c HS treatment, d Q treatment, e HS+Q treatment. TUNEL staining, X20 (Arrow: apoptotic cell)

In the treatment groups, hepatocyte regeneration was detected with more positivity when the rate in the HS group was compared with the control group ($p < 0.01$); when the Q group was compared with the control group ($p < 0.001$); and when Q+HS group was compared with the control group with statistical significance identified ($p < 0.0001$) (Fig. 6).

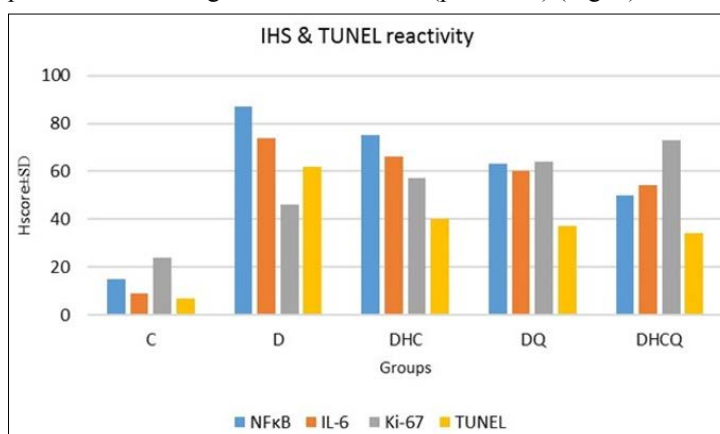


Figure 6: Distribution of immunoreactivity with immunohistochemical staining and apoptotic reactivity in the TUNEL assay of liver tissues. C = Control, D = Diabetes, DHC = Diabetes + Moss, DQ = Diabetes+Quercetin, DHCQ = Diabetes+Moss+Quercetin

Biochemical Findings

Catalase enzyme activity in the liver tissue of untreated diabetic rats was lower than in normal rats. Catalase levels increased significantly in all treatment groups compared to normal and untreated diabetic rats, showing the highest levels in the DHSQ group. Diabetic animals exhibited a significant reduction in SOD activity compared to controls. In diabetic animals treated with HS and Q, SOD activity showed a dose-dependent increase. The highest increase was observed in the HS+Q group. In addition, animals with diabetes-induced with STZ showed a significant decrease in serum C-peptide level compared to the control group. Serum C-peptide level significantly increased with HS and Q administration, with a considerable increase compared to the diabetic and normal groups. Meanwhile, daily co-administration of sitagliptin with quercetin normalized the serum C-peptide level. Diabetic animals exhibited a significant increase in serum MDA level, reaching almost two times that of normal rats. However, serum MDA levels were significantly lower than in the diabetic group after daily treatment with HS and Q (Table 2).

Table 2: Biochemical analysis results

	Insulin	C-peptide	MDA	SOD	IFN-γ
Control	25.56	46.12	6.83	224.12	22.14
Diabetes	15.24	28.54	13.2	148.42	30.06
Diabetes+HS	20.72	38.42	9.25	180.24	28.54
Diabetes+Quercetin	22.31	42.65	8.05	189.24	27.79
Diabetes+ HS+ Quercetin	22.84	44.81	6.63	202.47	25.53

Discussion

DM is a metabolic disease characterized by the permanent destruction of pancreatic beta cells. This destruction causes degranulation and a decrease in insulin secretion [31]. This study aimed to evaluate the antioxidant and anti-inflammatory properties of moss and quercetin administered orally for treatment, and the effects on the liver under light microscopy in rats with diabetes induced by STZ, including the changes in histopathological and biochemical parameters in the literature. In addition, the aim was to provide a different perspective on diabetes with the combined treatment option and to reveal alternative herbal products that will be more effective and have nutritional and medicinal properties that will enrich the quality of life of diabetes patients. There is no study investigating the histological and biochemical effects of STZ on the liver in rats with diabetes previously induced. This study showed that high blood glucose levels, dyslipidemia, inflammation in the liver, and apoptosis could be prevented. The effects of diabetes on the liver include ultrastructural changes such as hypertrophy of hepatocytes and the appearance of autophagic vacuoles. The hepatocyte nucleus is usually enlarged, sometimes with irregular contours and an appearance containing intranuclear inclusions. In the diabetic group, cytoplasmic changes are observed as decreased glycogen granules and an underdeveloped rough endoplasmic reticulum [32]. In our study, diffuse degeneration due to vacuolization and necrosis was observed in hepatocytes of diabetic rats under light microscopy. No increase in perisinusoidal fibrous and collagenous material was observed in any group. In a previous study, it was reported that fibrosis was observed in the diabetic liver. However, some authors claimed that fibrosis in the diabetic liver is not directly related to diabetes but due to liver vascular anomalies and genetic predisposition in the studied rat lineage [32]. Fibrosis was not observed in the liver findings in our study. When the degenerative picture in which cytoplasmic vacuolization became widespread is examined, it was in parallel with the results reported in other studies.

In the present study, diabetic rats exhibited a significant increase in blood glucose with a substantial decrease in serum levels of C-peptide. The combination of moss and quercetin returned these parameters to average values, reflecting its potential effect on glucose homeostasis. The administration of moss alone caused a significant decrease in glucose level, while the C-peptide level significantly increased. When quercetin was given alone, it produced a considerable effect, as shown by the reduction in glucose level and the increase in serum levels of C-peptide [11]. This effect may be related to improving whole-body insulin sensitivity by increasing the expression and phosphorylation of glucose transport-4 and insulin receptors and substrate [12]. Quercetin also increases blood glucose uptake by hepatic cells by activating hexokinase and adenosine monophosphate-activated protein kinase [13]. In addition, quercetin was reported to lower blood sugar by increasing the proliferation of pancreatic β -cells in STZ-induced diabetic rats [34].

Plants and compounds isolated from plants are effective in controlling DM complications. This study showed that quercetin and moss extract, which are plant-derived compounds, have a synergistic antidiabetic effect in diabetes by improving glucose metabolism enzymes. Overall, STZ is considered an optimal model for inducing diabetes in animals. STZ induces diabetes by a mechanism involving its depletion by pancreatic beta cells, producing excessive ROS that leads to diabetic symptoms such as hyperlipidemia and hyperglycemia [35]. Therefore, we used this model to develop DM in Wistar rats. To overcome the hyperglycemic effect in rats, they were treated with 50 mg/kg Q and 100 mg/kg HS doses. The treatment doses were determined based on body mass index and the available literature about both compounds. The compounds were therapeutically effective at reducing the hyperglycemic effect in STZ-induced diabetic rats. Noted that quercetin could reduce hyperglycemia of pancreatic islets to release enough insulin. It is known to strengthen the pancreatic islets of Langerhans to produce flavonoids, insulin, and glucagon and secrete them into the bloodstream [36].

The liver is a central metabolic organ and is exposed to reactive oxygen species formed due to oxidative damage caused by diabetes. For this reason, it was suggested that apoptosis occurs in hepatocytes and endothelial cells [37]. In diabetes studies using STZ, necrosis in hepatocytes, inflammatory cell infiltration, lipodosis, dilatation in sinusoids, and disorders in portal spaces are reported findings. In the present study, similar results were observed in rats in the diabetes group. These findings significantly reduced with treatment using moss and quercetin [38].

In a study administering quercetin to male rats with experimental diabetes mellitus induced with STZ, quercetin played a stabilizing role in blood sugar control [19]. In another study examining the effect of quercetin on protein and lipid damage in experimental diabetic rats, quercetin did not have a practical protective feature against protein damage caused by DM but had a protective role against lipid peroxidation. In a study administering quercetin to rats, it prevented the formation of free oxygen radicals in cells and protected against lipid peroxidation [20]. In addition to studies that reported that quercetin administration inhibited lipid peroxidation, there are also studies reporting it reduced lipid peroxidation in human lymphocytes [21].

Studies showed that low-grade inflammation is associated with an increased risk of developing type 2 diabetes mellitus. In addition, chronic subclinical inflammation is a factor in the development of insulin resistance, a vital feature of metabolic syndrome [3, 39]. Throughout a trial, Wong et al. studied the effect on the regulation of glucose metabolism and body weight by feeding IFN- γ -deficient mice with standard low-fat mouse chow and observed reduced body weight was associated with negative energy balance, glucose tolerance, and hepatic insulin sensitivity in mice. The researchers stated that IFN- γ plays a vital role in regulating glucose metabolism and weight gain [5]. Obese IFN-

γ -knockout mice were found to exhibit milder insulin resistance, reduced adipocyte size, M2-related cytokine expression in adipose tissue compared to healthy mice, and IFN- γ was associated with glucose homeostasis, adipogenesis, and cytokine expression in adipose tissue [4]. These studies show that the IFN- γ level, which is essential in terms of glucose tolerance and hepatic insulin sensitivity, was significantly different between the diabetic group in our research and the treatment groups. IFN- γ , which was highest in the diabetes group, decreased in the HS+Q group. The survey conducted by Pradhan et al. showed that increased inflammatory biomarkers are associated with the development of type 2 diabetes and insulin resistance [6]. Although the mechanism by which chronic inflammation stimulates the development of type 2 diabetes mellitus is not fully understood, it was shown that adipose tissue can synthesize tumor necrosis factors, major proinflammatory cytokines such as interleukin-1, and interleukin-6 and that the inflammatory process is associated with biomarkers for body fat mass. This suggests that activated innate immunity and inflammation are essential biological factors in the pathogenesis of diabetes mellitus and complications of type 2 diabetes mellitus [7]. Pitsavos et al. recruited 3042 subjects (1514 men and 1528 women) in a randomized controlled trial to investigate the survival impact of type 2 diabetes inflammatory biomarkers. The authors reported an association between low-grade markers of inflammation and glycemic control parameters, independent of demographic, clinical, and lifestyle indices such as dietary factors.

Type 2 diabetes is associated with impaired glucose tolerance due to insulin resistance; concomitant islet beta-cell damage can lead to insulin deficiency, affecting glucose utilization by skeletal muscle, liver, and adipose tissues [9]. Therefore, impaired glucose tolerance and other factors such as genetic predisposition, environmental characteristics, diet, physical inactivity, and obesity contribute significantly to the progression of insulin resistance and the development of type 2 diabetes [6, 7, 10].

Studies on the level of 8-hydroxy-deoxyguanosine-modified proteins in GK-rats and Tucker diabetic rats, respectively, showed that hyperglycemia was the main potential factor for oxidative stress in pancreatic beta cells, and glucose-induced oxidative stress explained the mechanism behind glucotoxicity [40]. In our study, hyperglycemia was observed in diabetic rats. It manifested itself with an almost 4-fold significant increase in serum blood glucose level compared to the control group. The treatment groups with daily HS and Q had significantly lowered serum glucose levels. Co-administration of both agents significantly normalized the serum glucose level compared to the diabetic group. In addition, STZ-induced animals showed a significant decrease in serum C-peptide level compared to the control group. Serum C-peptide level significantly increased with HS and Q administration and there was a considerable increase compared to the diabetic and normal groups. Meanwhile, daily co-administration of sitagliptin with quercetin normalized the serum C-peptide level.

As can be seen, much experimental evidence highlights a direct link between oxidative stress and diabetes through the measurement of oxidative stress biomarkers in both diabetic patients and rodents. In our study too, diabetic animals exhibited a significant increase in serum MDA level, which reached almost twice that of normal rats. After daily treatment with HS and Q, serum MDA level was significantly lower than in the diabetic group. When MDA level was compared with the diabetic group, it approached normal when both agents were administered together. Catalase enzyme activity in the liver tissue of untreated diabetic rats was lower than in normal rats. Catalase levels increased significantly in all treatment

groups compared to normal and untreated diabetic rats, showing the highest levels in the DHSQ group. Diabetic animals exhibited a significant reduction in SOD activity compared to controls. In diabetic animals treated with HS and Q, SOD activity showed a dose-dependent increase. The highest increase was observed in the HS+Q group.

Our study showed that taking moss extract together with an agent with known antioxidant properties such as quercetin can prevent liver damage. These results may shed light on the prevention of the third leading indication for liver transplantation in the USA of cryptogenic cirrhosis, the most common cause of which is diabetes.

A study on the relationship between inflammation, oxidative stress, and type 2 diabetes suggested that controlling inflammation and oxidative stress is necessary to accelerate the treatment process and prevent diabetic complications [37]. Again, were more precise about the type of evolution of diabetes [6]. Specifically, the authors reported conversion from a metabolic disorder to an inflammatory state. These studies show that blood glucose levels, oxidative stress, and inflammatory cytokines play a significant role in type 2 diabetes and liver damage diabetes. As can be understood from all these studies, hyperglycemia increases the production of free radicals resulting in oxidative stress. Increases in oxidative stress are known to contribute to the development and progression of hepatic complications in diabetes. Evidence supporting the role of inflammation in type-2 diabetes is increasingly being found in studies. Inflammatory cells and cytokines are involved in the pathogenesis of diabetic complications through increased vascular inflammation and fibrosis. Although the causes of increased inflammation in diabetes are still being investigated, reactive oxygen species were shown to be primary candidates. Therefore, we believe that targeting oxidative stress and inflammatory cytokine signaling may improve therapeutic options for diabetes and diabetic complications.

Conclusions

In this study, findings with implications for new combined therapy for diabetes mellitus are presented. For the first time, moss and quercetin were used in an in vivo study. As a result, the antioxidant, and anti-inflammatory properties of moss, which is one of the agents selected for protective purposes, were revealed for the first time. Furthermore, it was observed that glucose homeostasis can be normalized with the combination of moss and quercetin, and lipid profile and inflammation act retroactively with increased antioxidant power.

Acknowledgements

The authors are grateful to their institutions for the opportunity to develop this publication

Author Contribution

OTY sample collection, writing; ŞÖ methodology; LCI data curation; ND conceptualization. All the authors approved the final version of the manuscript.

Financial Disclosure

The author(s) disclosed receipt of the following financial support for the research, authorship, and/or publication of this article: This work was supported by Canakkale Onsekiz Mart University, Scientific Research Project (BAP/FBA-2020-3314).

Ethical Approval

All applicable international, national, and/or institutional guidelines for the care and use of animals were followed by

Canakkale Onsekiz Mart University Ethics Committee for Animal Research (Protocol number: 2020-04/05).

Conflict of Interest

The authors declare that they have no conflict of interest.

References

1. Chen L, Magliano DJ, Zimmet PZ (2011) The worldwide epidemiology of type 2 diabetes mellitus-present and future perspectives. *Nat Rev Endocrinol* 8: 228-236.
2. Salihu OA, Oguntibeju M, Esterhuysen O, Olatunde AJF, Oyagbemi AA (2014) Some Selected Medicinal Plants with Antidiabetic Potentials. Ed. by Oluwafemi Oguntibeju, Antioxidant-Antidiabetic Agents and Human Health IntechOpen. <https://doi.org/10.5772/57230>
3. Bloomgarden ZT (2003) Inflammation and insulin resistance. *Diabetes Care* 26: 1922-1926.
4. Radetti G, Frizzera S, Castellan C, Mengarda G (2004) Bone density in swimmers. *Pediatr Med Chir* 14: 521-522.
5. Pickup J, Crook M (1998) Is type II diabetes mellitus a disease of the innate immune system?. *Diabetologia* 41: 1241-1248.
6. Navarro JF, Mora C (2005) Role of inflammation in diabetic complications. *Nephrol Dial Transplant* 20: 2601-2604.
7. Demircan N, Safran BG, Soyulu M, Ozcan AA, Sizmaz S (2006) Determination of vitreous interleukin-1 (IL-1) and tumour necrosis factor (TNF) levels in proliferative diabetic retinopathy. *Eye* 20: 1366-1369.
8. Schmidt MI, Duncan BB, Sharrett AR, Lindberg G, Savage PJ, et al. (1999) Markers of inflammation and prediction of diabetes mellitus in adults (Atherosclerosis Risk in Communities study): a cohort study. *Lancet* 353: 1649-1652.
9. Spranger J, Kroke A, Mohlig M, Hoffmann K, Bergmann MM, et al. (2003) Inflammatory cytokines and the risk to develop type 2 diabetes: results of the prospective population-based European Prospective Investigation into Cancer and Nutrition (EPIC)-Potsdam Study. *Diabetes* 52: 812-817.
10. Pieper GM (1997) Activation of nuclear factor-kappa B in cultured endothelial cells by increased glucose concentration: prevention by calphostin C. *J Cardiovasc Pharmacol* 30: 528-532.
11. Abdelkader NF, Eitah HE, Maklad YA, Gamaleldin AA, Badawi MA, et al. (2020) New combination therapy of gliclazide and quercetin for protection against STZ-induced diabetic rats. *Life Sci* 247: 117458.
12. Shi GJ, Li Y, Cao QH, Wu HX, Tang XY, et al. (2018) In vitro and in vivo evidence that quercetin protects against diabetes and its complications: A systematic review of the literature. *Biomed Pharmacotherapy* 109: 1085-1099.
13. Oyedemi SA, Nwaogu G, Chukwuma CI, Adeyemi OT, Matsabisa MG, et al. (2020) Quercetin modulates hyperglycemia by improving the pancreatic antioxidant status and enzymes activities linked with glucose metabolism in type 2 diabetes model of rats: In silico studies of molecular interaction of quercetin with hexokinase and catalase. *J Food Biochem* 44: e13127.
14. Dabeek WM, Marra MV (2019) Dietary Quercetin and Kaempferol: bioavailability and potential cardiovascular-related bioactivity in humans. *Nutrients* 11: 2288.
15. Chen C, Zhou J, Ji C (2010) Quercetin: a potential drug to reverse multidrug resistance. *Life Sci* 87: 333-338.
16. Shabbir U, Rubab M, Daliri EB, Chelliah R, Javed A, et al. (2021) Curcumin, Quercetin, Catechins and Metabolic Diseases: The Role of Gut Microbiota. *Nutrients* 13: 206.
17. Kumar S, Sharma H, Yadav K (2016) Quercetin and metabolic syndrome. *EJPMR* 3:701-709.
18. Eitah HE, Maklad YA, Abdelkader NF, El Din AAG, Badawi MA, et al. (2019) Modulating impacts of quercetin/sitagliptin combination on streptozotocin-induced diabetes mellitus in rats. *Toxicol Appl Pharmacol* 365: 30-40
19. Kim JH, Kang MJ, Choi HN, Jeong SM, Lee YM, et al. (2011) Quercetin attenuates fasting and postprandial hyperglycemia in animal models of diabetes mellitus. *Nutr Res Pract* 5: 107-111.
20. Manach C, Texier O, Morand C, Crespy V, Régérat F, et al. (1999) Comparison of the bioavailability of quercetin and catechin in rats. *Free Radical Biology and Medicine* 27: 1259-1266.
21. Gargouri B, Mansour RB, Abdallah FB, Abdelfetteh Elfekih, Saloua Lassoued, et al. (2001) Protective effect of quercetin against oxidative stress caused by dimethoate in human peripheral blood lymphocytes. *Lipids Health Dis* 10: 149.
22. Cassady JM, Chan KK, Floss HG, Leistner E (2004) Recent developments in the maytansinoid antitumor agents. *Chemical Pharmaceutical Bulletin* 52: 1-26.
23. Krzaczkowski L, Wright M, Reberieux D, Massiot G, Etievant C, et al. (2009) Pharmacological screening of bryophyte extracts that inhibit growth and induce abnormal phenotypes in human HeLa cancer cells. *Fundamental Clinical Pharmacology* 23: 473-482.
24. Saxena D, Harinder D (2004) Uses of bryophytes. *Resonance* 9: 56-65.
25. Belkin M, Fitzgerald D, Felix MD (1952) Tumor damaging capacity of plant material II. Plants used as diuretics. *J. Natl. Cancer Institute* 3: 741.
26. Asakawa Y (2007) Biologically active compounds from bryophytes. *Pure and Applied Chemistry* 79: 557-580.
27. Ivanova V, Kolarova, M, Aleksieva, K, Dornberger KJ (2007) Sanionins: Anti-inflammatory and antibacterial agents with weak cytotoxicity from the Antarctic Moss *Sanionia georgico uncinata*. *Preparative Biochemistry and Biotechnology* 37: 343-352.
28. Rosa M Ros, Vicente Mazimpaka, Usama Abou-Salama, Michele Aleffi, Thomas L Blockeel, et al. (2013) Mosses of the Mediterranean, an annotated checklist. *Cryptogamie Bryologie* 34: 99-283.
29. Jonathan AS (2004) Reflecting on the development of interpretative phenomenological analysis and its contribution to qualitative research in psychology. *Qualitative Research in Psychology* 1: 39-54.
30. Öztürk Ş, Kiliçaslan Sönmez P, Özdemir İ, Topdağı YE, Tuğlu Mİ (2019) Antiapoptotic and proliferative effect of bone marrow-derived mesenchymal stem cells on experimental Asherman model. *Cukurova Medical Journal* 44: 434-446.
31. Jaishree V, Narsimha S (2020) Swertiamarin and quercetin combination ameliorates hyperglycemia, hyperlipidemia, and oxidative stress in streptozotocin-induced type 2 diabetes mellitus in Wistar rats. *Biomed Pharmacotherapy* 130: 110561.
32. Kume E, Fujimura H, Matsuki N, Ito M, Aruga C, et al. (2004) Hepatic changes in the acute phase of streptozotocin (SZ)-induced diabetes in mice. *Exp Toxicol Pathol* 55: 467-480.
33. Brůha R, Dvořák K, Petrtyl J (2013) Liver disorders in diabetic patients. *Vnitr Lek* 59: 546-550.
34. Vessal M, Hemmati M, Vasei M (2003) Antidiabetic effects of quercetin in streptozocin induced diabetic rats. *Comp Biochem Physiol C Toxicol Pharmacol* 135: 357-364.
35. Furman BL (2015) Streptozotocin-induced diabetic models in mice and rats. *Curr Protoc Pharmacol* 70: 5-47.

36. Mukhopadhyay P, Prajapati AK (2015) Quercetin in anti-diabetic research and strategies for improved quercetin bioavailability using polymer-based carriers—a review. RSC Advances 5: 97547-97562.
37. Zhang C, Lu X, Tan Y, Li B, Miao X, Jin L, et al. (2012) Diabetes-induced hepatic pathogenic damage, inflammation, oxidative stress, and insulin resistance were exacerbated in the zinc-deficient mouse model. Plos One 7: e49257.
38. Noor A, Gunasekaran S, Manickam AS, Vijayalakshmi MA (2008) Antidiabetic activity of Aloe vera and histology of organs in streptozotocin-induced diabetic rats. Current Sci 94: 1070-1076.
39. Dandona P, Aljada A, Bandyopadhyay A (2004) Inflammation: the link between insulin resistance, obesity and diabetes. Trends Immunol 25: 4-7.
40. Tanaka Y, Gleason Ce, Tran PO, Harmon JS, Robertson RP (1999) Prevention of glucose toxicity in HIT-T15 cells and Zucker diabetic fatty rats by antioxidants. Proc Natl Acad Sci USA 96: 10857-10862.

Copyright: ©2022 Ozlem Tonguc Yayintas, et al. This is an open-access article distributed under the terms of the Creative Commons Attribution License, which permits unrestricted use, distribution, and reproduction in any medium, provided the original author and source are credited.