

8-31-2021

## Evaluation of the Bone Thickness of Mandibular Molars using Cone Beam Computed Tomography

Deniz Yanık

*Department of Endodontics, School of Dentistry, Antalya Bilim University, 07190, Antalya, Turkey.,  
deniz.yanik@antalya.edu.tr*

Ahmet Mert Nalbantoglu

*Department of Periodontology, School of Dentistry, Antalya Bilim University, 07190, Antalya, Turkey.,  
mert.nalbantoglu@antalya.edu.tr*

Follow this and additional works at: <https://scholarhub.ui.ac.id/jdi>



Part of the [Dental Hygiene Commons](#), [Endodontics and Endodontology Commons](#), [Oral and Maxillofacial Surgery Commons](#), [Oral Biology and Oral Pathology Commons](#), and the [Periodontics and Periodontology Commons](#)

---

### Recommended Citation

Yanık, D., & Nalbantoglu, A. M. Evaluation of the Bone Thickness of Mandibular Molars using Cone Beam Computed Tomography. *J Dent Indones.* 2021;28(2): 82-87

This Article is brought to you for free and open access by the Faculty of Dentistry at UI Scholars Hub. It has been accepted for inclusion in *Journal of Dentistry Indonesia* by an authorized editor of UI Scholars Hub.

---

## Evaluation of the Bone Thickness of Mandibular Molars using Cone Beam Computed Tomography

### Cover Page Footnote

CONFLICT OF INTERESTS The authors declare that they have no conflict of interest.

**ORIGINAL ARTICLE**

## **Evaluation of the Bone Thickness of Mandibular Molars using Cone Beam Computed Tomography**

**Deniz Yanık<sup>1</sup>, Ahmet Mert Nalbantoğlu\*<sup>2</sup>**

<sup>1</sup>*Department of Endodontics, School of Dentistry, Antalya Bilim University, 07190, Antalya, Turkey.*

<sup>2</sup>*Department of Periodontology, School of Dentistry, Antalya Bilim University, 07190, Antalya, Turkey.*

\*Correspondence e-mail to: mert.nalbantoglu@antalya.edu.tr

### **ABSTRACT**

**Objective:** To investigate buccal and lingual bone thicknesses and fenestration rate of mandibular first and second molars using cone-beam computed tomography (CBCT). **Methods:** A total of CBCT images of 41 patients were selected and overall 120 mandibular molars were investigated. The buccal and lingual alveolar bone widths were measured at apex of the roots. The prevalence of fenestration in mandibular molars was recorded. Statistical analyses were performed. **Results:** The buccal bone widths of mesial root of second molars were significantly lower than the lingual ( $p<0.05$ ). The lingual bone widths of mesial and distal root of second molars were lower than the buccal ( $p<0.05$ ). The lowest thickness of buccal and lingual bone was observed in mesial root of first molar and distal root of second molar. The prevalence of fenestration in mandibular first and second molars was 5% and 10%. **Conclusion:** The buccal bone widths were lower at the first molar than the second molar. All fenestrations in first molar were in buccal aspect, in second molar were in lingual aspect. Topographical proximity of the buccal side of first molar and the lingual side of second molar to bone plate create a risky region for endodontic treatment or spread of infection.

**Key words:** anatomy, cone beam computed tomography, mandible, alveolar process, dental implant

How to cite this article: Yanık D, Nalbantoğlu AM. Evaluation of the bone thickness of mandibular molars using cone beam computed tomography. *J Dent Indones.* 2021;28(2):82-87.

### **INTRODUCTION**

The thickness of the alveolar bone surrounding the teeth is one of the most influential variables affecting the spread of odontogenic infections.<sup>1</sup> Periradicular endodontic infections are the most commonly seen odontogenic pathologies. The infected root canal, under untreated conditions, creates consistent microbial irritation to periapical tissues result in periradicular diseases.<sup>2</sup>

Fenestration is a circumscribed anatomical bone variation that exposes the surface of the root. According to the American Association of Endodontists (AAE) definition, fenestration is usually located in the buccal aspect of the alveolar bone. However, a former study showed that fenestration can be seen in the lingual/palatinal aspect (5.5%) as well as in the buccal region (94.5%), albeit at a low rate.<sup>3</sup> On the other hand, with regard to the apical-coronal position, most of the fenestrations are located at the apical half of the root.<sup>4</sup> Apical fenestrations concern the health of

pulp, periapical tissues, and oral mucosa since they provide a communication pathway between these regions. Although they are generally asymptomatic, in the case of odontogenic infection or endodontic treatment, they can cause pain and accelerate the spread of infection to soft tissues.<sup>5</sup> Therefore, the lingual bone thickness of mandibular teeth, the topographic proximity of the apex to the lingual bone plate, and the presence of fenestration, especially in the apical half, are substantial factors concerning the spread of an endodontic infection, the long-term success of endodontic treatment and the accessibility of the region for endodontic surgery.

Cone-beam computed tomography (CBCT) provides a three-dimensional investigation of alveolar structures without superimposition and distortion of alveolar bone. In the literature, good to excellent accuracy of CBCT for alveolar bone thickness measurements have been previously reported.<sup>6,7</sup> Thus, the authors of the

present study investigated the lingual bone thickness and the fenestrations at the mandibular molar teeth using the CBCT imaging technique.

Previous studies have generally focused on mandibular third molars, because of the complications including the fracture of the lingual bone plate during extraction and spread of infection into anatomical spaces.<sup>8</sup> However, the lingual bone thickness of mandibular first and second molars is an important marker for the spread of infection. On the other hand, previous studies in the literature that investigate the presence of fenestration on dry skull or CBCT indicate fenestration rate without the information that involves the belongingness to mesial and distal root.<sup>3-5</sup> The purpose of the present study was to investigate the lingual and buccal bone thickness of the mandibular first and second molar at apex level and to determine the frequency of fenestrations using CBCT.

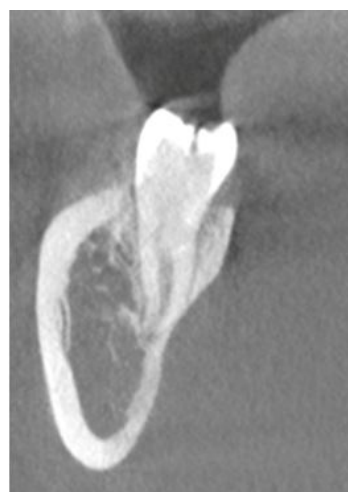
## METHODS

For purpose of the present study, a retrospective CBCT study was designed. The research protocol of the present study was approved by the local ethics and research committee. The overall protocol of the present study was performed in accordance with the guidelines outlined in the Declaration of Helsinki. The present study subjects consisted of CBCT images of 41 patients (22 females and 19 males) aged 24-44 years (mean age  $32.5 \pm 2$ ). CBCT images were collected from the database of the oral and maxillofacial radiology department of the university dental clinic from February 2020 to January 2021. Non-smoking healthy patients without systemic disease were included. Patients with previous orthodontic treatment, mandibular deformities, mandibular molars with endodontic treatment, extensive carious lesion, periapical lesion, under-developed root, open-apex, external resorption, root fracture were excluded. CBCT images of poor quality and has artifacts were also excluded from the study. For the study, 120 first ( $n=60$ ) and second ( $n=60$ ) mandibular molars were selected. The thickness of the buccal and lingual bone at the mandibular molars was retrospectively measured (Figure 1,2).

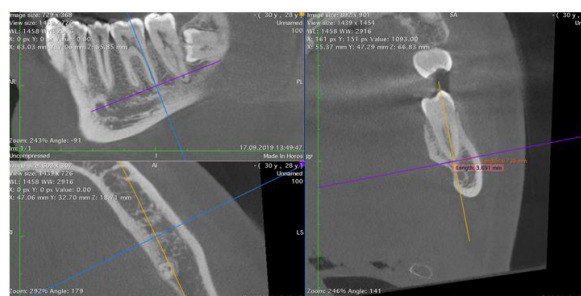
### Radiographic image analysis

CBCT images on axial, coronal, and sagittal planes were taken from Orthophos (Sirona Dental Systems, Bensheim, Germany). Imaging parameters were set as 85 kVp, 6 mA, 14.1 sn exposure time, 0.2 mm voxel size, and 80 x 40 mm field of view. The images were analyzed, and the measurements were performed using Horos 3.0 software (Horos Project, Annapolis, Maryland USA).

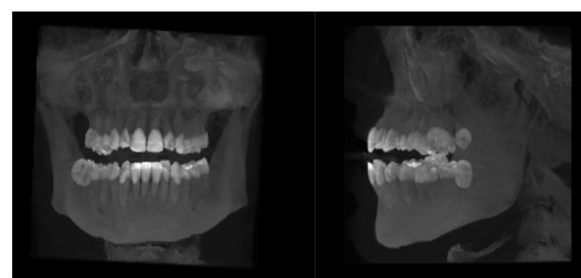
All measurements were performed by two observers independently. The axial guided navigation method was



**Figure 1.** CBCT image showing lingual fenestration of mandibular second molar in the coronal plane.



**Figure 2.** Buccal and lingual bone thickness measurements at apex level in sagittal, coronal, and axial planes.



**Figure 3.** Three-dimensional reconstruction for detection of fenestrations

used to determine the cross-section to be measured and to standardize the calibration of observers.<sup>9</sup> Besides, for calibration, 10 % of the images was evaluated, and the kappa score was stated (range from 0.89 to 0.93). All measurements were performed twice by one observer, and the averages were accepted for statistical analysis. The measurements of three subjects were performed at one time, after every three measurements, a break was made to eliminate eye fatigue of observers. The buccal and lingual bone thicknesses were measured at the root apex perpendicular to the long axis of the tooth. Fenestrations detected in two-dimensional axial sections were confirmed by three-dimensional reconstructions (Figure 3).

**Table 1.** The buccal and lingual alveolar bone thicknesses of mandibular first and second molars at apex level

			Alveolar Bone Thickness				
			Mean	Std	Min	Max	
Apex of The Root	Lingual	First molar	Mesial	5.56	1.85	0.69	9.27
			Distal	4.69 <sup>a</sup>	1.78	0.91	8.2
		Second molar	Mesial	2.5 <sup>d</sup>	1.47	0.31	7.67
			Distal	2.44 <sup>e</sup>	1.44	0	5.24
	Buccal	First molar	Mesial	3.13 <sup>b,c</sup>	1.69	0.34	10.96
			Distal	4.77	1.76	1.33	9.14
		Second molar	Mesial	7.53	1.97	3.12	12.53
			Distal	7.78	2.1	1.14	11.43

<sup>a</sup>According to Student's t- test significant difference was found when compared with mesial and distal root in lingual side of 1st molar (p= 0.023).

<sup>b</sup>Significant difference was found when compared with mesial and distal roots in buccal side of 1st molar,

<sup>c</sup>significant difference was found when compared with buccal and lingual sides in mesial root of 1st molar,

<sup>d</sup>significant difference was found when compared with buccal and lingual sides in mesial root of 2nd molar,

<sup>e</sup>significant difference was found when compared with buccal and lingual sides in distal root of 2nd molar (p= 0.000).

### Statistical Analysis

Statistical analysis was performed using SPSS version 22.0 for Windows (IBM Corp., Armonk, NY, USA). The mean, maximum, minimum, and standard deviation of the quantitative variables were assessed. The normality distribution of the obtained data was analyzed by the Levene's test. Student's t-test was used to compare the data between the lingual and buccal bone thicknesses of mandibular first and second molar. Intraclass and interclass correlation coefficient (ICC) was used for observer reliability.

### RESULTS

For the first and second mandibular molars, the thicknesses of buccal and lingual alveolar bone at the apical of the mesial and distal roots were presented in Table 1. According to Student's t- test, a statistically significant difference was found between the buccal and lingual alveolar bone widths of the distal and mesial roots of the first mandibular molar (p<0.05). The thickness of the buccal alveolar bone in the mesial root of the first molar was significantly lower than the distal root of the first molar. The thickness of the lingual alveolar bone in the distal root of the first molar was significantly lower than the mesial root of the first molar. There is no statistical difference in the thickness of buccal and lingual alveolar bone between mesial and distal root apical levels in the second molar (p>0.05), while there is a significant difference in the first molar (p<0.05).

A statistically significant difference was found between the lingual and buccal alveolar bone widths of the distal and mesial roots of second mandibular molars (p<0.05). A statistically significant difference was found between the lingual and buccal alveolar bone thickness of the mesial root of the first mandibular molars (p<0.05). The lingual bone thickness of the distal and mesial roots of second molar was significantly lower than the buccal bone thickness (p<0.05). The buccal alveolar bone thickness of the mesial root of first molar was significantly lower than the lingual alveolar bone thickness (p<0.05).

There is no statistical difference in the thickness of lingual and buccal alveolar bone in the distal root of the mandibular first molars (p>0.05). No significant differences in bone thickness were observed between genders or the right and left sides.

The mean thicknesses of buccal alveolar bone in mandibular first molars at the apical level of the mesial and distal root were 3.13 mm and 4.77 mm, respectively. The mean thicknesses of lingual alveolar bone of the mesial and distal root of first molars were 5.56 mm and 4.69 mm respectively. The mean thicknesses of buccal alveolar bone in the mesial and distal root of second molars were 7.53 mm and 7.78 mm, respectively. The mean thicknesses of lingual alveolar bone of the mesial and distal root of second molars were 2.50 mm and 2.44 mm respectively. To the descriptive analysis, the highest thickness of lingual alveolar bone was observed in the first molars at the mesial root. And the highest

**Table 2.** The fenestration rates of buccal and lingual aspects of first and second molars

Tooth		Apical Fenestration (%)		
		Total	Buccal	Lingual
First molar	Mesial	5	3.3	0
	Distal		1.7	0
Second Molar	Mesial	10	0	3.3
	Distal		0	6.7

thickness of buccal bone was observed in second molars at the distal root.

The overall prevalence of fenestration in mandibular first and second molars was found as 5 % (all in buccal aspect) and 10 % (all in lingual aspect), respectively (Table 2). There is no statistically significant difference was found between mandibular first and second molars ( $p > 0.05$ ). The ICC for the measurements of the bone thickness of mandibular molars were ICC=0.979 and ICC=0.989, respectively ( $p < 0.001$  for all ICC values).

## DISCUSSION

Chronic persistence of an endodontic pathology leads to the formation of a sinus tract. The buccal and lingual bone thickness of the mandibular region and the spatial proximity of the root apex to the facial spaces directly affect the spread of infection of mandibular molars. According to the anatomy literature, mandibular molars are generally located in the lingual part of the mandible, but the detailed determination of the bone thicknesses of each root in the first and second molars enables a clinical interpretation of the sinus tract that determines the spread of pathology to facial spaces.<sup>10</sup> The present study evaluated buccal and lingual bone thickness of the distal and mesial roots of mandibular molars. The results of the present study indicated that the buccal of the mesial root of the first molar is thinner compared to lingual aspect, while the lingual thickness of both two roots of the second molar is thinner compared to buccal aspect. The authors of the present study emphasize that an infection originating from the mesial root of the first molar can create a sinus tract toward the buccal direction, conversely, an infection of the distal root can drain from both directions. For the second molar, the drainage pathway exits through the lingual direction for both roots.

On the other hand, in the case of extraction for periodontal or endodontic reasons, a pre-extraction alveolar bone thickness of 2 mm is required for optimum healing of the implant.<sup>11</sup> However, as shown in the present study, the lingual bone of the mandibular second molar is significantly thinner than the buccal

bone. Therefore, it is essential to evaluate the bone morphology of this region in the case of immediate implant placement by three-dimensional imaging techniques to avoid bone perforations.

CBCT is regarded as a highly accurate cross-sectional imaging technique to measure the bone thickness. This imaging modality enables to rule out direct measurement errors caused by the effects of bone irregularities and the presence of surrounding tissues, as well as easily allowing repeatable measurements by different observers and at different intervals.<sup>12,13</sup> For this reason, in the present study, CBCT measurements were used to investigate bone thickness.

Endodontic surgery is a substantial treatment option performed in the failure of nonsurgical endodontic treatments. In endodontic surgery, it has been shown that cortical bone is the last healing region with a recovery rate of 70%.<sup>14</sup> Besides, a previous study using CBCT reported that bone healing is 50% after endodontic surgery.<sup>15</sup> The mesial root of the mandibular first molar, where the buccal bone is already thin, as concluded in the present study, is a potentially risky area with regards to the formation of bone defects after surgery. On the other hand, the apical of the root of mandibular molars is closer to lingual space. Surgical access line (SAL) is a perpendicular line that starts at the tip of the apex and continued throughout the overall thickness of the buccal bone.<sup>16</sup> The present study showed that the mean buccal bone thickness of the mandibular second molar, described as the SAL, was 7.65 mm. The overlying thick buccal bone plate of mandibular second molars limits access to the apical region. Thus, buccal bone thickness is an essential factor for endodontic surgery. Previous studies in different populations using CBCT and CT have reported the buccal thicknesses at the distal root of the mandibular second molar were 6.31 mm, 9.60 mm, and 8.51 mm, whereas in the present study this value was 7.78 mm.<sup>17,18,19</sup> The present study also stated that the thickest bone on the buccal aspect was at the distal root of the mandibular second molar. This result is congruent with previous reports in literature state that the bone thickness in the distal root of the mandibular second molar was the highest.<sup>17,18,19</sup> This result is related to the presence of an anatomically located external oblique ridge in this part of the mandible. This anatomic structure not only restricts surgical access to the region but also hampers the formation of the buccal drainage path of an endodontic infection.

When evaluated with regard to lingual bone thickness, in the present study, the thinnest bone in the lingual aspect of the posterior mandible was observed in the distal root of the mandibular second molar with a mean of 2.44 mm. This result is in contrast to a previous study that state the thinnest lingual bone was in the premolar

region.<sup>17</sup> However, another study examining the same racial population reported the thinnest region was the distal root of the mandibular second molar.<sup>20</sup> This reveals the influence of racial factors and procedural differences. The thin bone in the lingual aspect of the root apex of the mandibular molars may be related to the tooth inclination and the presence of anatomical formations like the submandibular fossa. On the other hand, the fact that the distal root of the second molar is the thinnest area in the lingual aspect of the posterior mandible may result in a lingual drainage path of the endodontic abscess of this tooth.

Tooth inclination, the proximity of anatomic structures, and bone morphology affect the bone thickness and the formation of bone defects like fenestration.<sup>21</sup> The present study evaluated that the presence of bone perforations in mandibular molars and stated the prevalence of fenestrations in first and second molars was 5% and 10%, respectively. Furthermore, in the present study, all fenestrations in the first and second molars were detected in the buccal aspect (100%) and lingual aspect (100%), respectively. Furthermore, 66% of all fenestrations in the first molars were detected in the mesial, while 67% of the second molars were detected in the distal. In the literature, previous studies using CBCT or dry skull reported the prevalence of fenestrations in mandibular molars ranging from 0% to 16% as listed in Table 3.<sup>22-26</sup> Moreover, in previous studies, the buccal and lingual measurements also affect the different results. A previous study that examined the same racial group, only examined the rate of lingual fenestration, unlike the present study. And according to the results of that study, the fenestration rate of the first and second molar was 2% and 13%, respectively. These results are similar to the results of our study, which found 0% and 10% lingual fenestration in the first and second molars, respectively. On the contrary, Nimigean et al.<sup>26</sup> reported the fenestration rate of first and second mandibular molar, with no lingual fenestration, was 16% and 1%, respectively. This result conflict with the results of the present study, which detected all fenestrations in the lingual aspect of the second molar. These various results of previous studies can be explained by the different methodologies and racial factors.

The limitation of our study includes the low sample size. The strength of our study was that to eliminate measurement errors, the presence of bone defects was confirmed with both two-dimensional slices and three-dimensional reconstructions independently. Further studies are needed with larger sample size.

Within the limitations of the present study, the data showed that, in the buccal aspect of the posterior mandible, the thickest bone was at the distal root of the second molar (7.78 mm), while the thinnest one

was at the mesial root of the first molar (3.13 mm, except the ones have fenestrations). In the lingual, the thickest and the thinnest bones were the mesial roots of the first molar (5.56 mm) and the distal root of the second molar (2.50 mm, except the ones have fenestrations), respectively. In addition, 10% of the root fenestration has been reported in the lingual of the mandibular second molar and 5% in the buccal of the first molar. Because of the topographic proximity of the root apex to the lingual and buccal bone plates, and the possible presence of bone perforations, clinicians should consider the three-dimensional examination when in the case of endodontic surgery of these teeth or in determining the source of infection in this area.

## CONFLICT OF INTERESTS

The authors declare that they have no conflict of interest.

## REFERENCES

1. Fragiskos D. (2007), Oral Surgery. 1st ed Springer - Verlag Berlin Heidelberg.
2. Siqueira JF. Endodontic infections: concepts, paradigms, and perspectives. *Oral Surg Oral Med Oral Pathol Oral Radiol Endod.* 2002;94(3):281-93.
3. Glossary of Endodontic Terms - American Association of Endodontists. Accessed February 11, 2021. <https://www.aae.org/specialty/clinical-resources/glossary-endodontic-terms/>
4. Rupprecht RD, Horning GM, Nicoll BK, Cohen ME. Prevalence of dehiscences and fenestrations in modern American skulls. *J Periodontol.* 2001;72(6):722-29.
5. Boucher Y. Persistent pain related to root canal filling and apical fenestration: A case report. *J Endod.* 2000;26(4):242-4.
6. Sun Z, Smith T, Kortam S, Kim DG, Tee BC, Fields H. Effect of bone thickness on alveolar bone-height measurements from cone-beam computed tomography images. *Am J Orthod Dentofacial Orthop.* 2011;139(2):117-27.
7. Pan HY, Yang H, Zhang R, et al. Use of cone-beam computed tomography to evaluate the prevalence of root fenestration in a Chinese subpopulation. *Int Endod J.* 2014;47(1):10-9.
8. Wang D, He X, Wang Y, Zhou G, Sun C, Yang L, et al. Topographic relationship between root apex of mesially and horizontally impacted mandibular third molar and lingual plate: cross-sectional analysis using CBCT. *Sci Rep.* 2016;6(1):1-10.
9. Castro LO, Castro IO, De Alencar AHG, Valladares-Neto J, Estrela C. Cone beam computed tomography evaluation of distance from cemento-enamel junction to alveolar crest before

- and after nonextraction orthodontic treatment. *Angle Orthod.* 2016;86(4):543-9.
10. Ohshima A, Arijji Y, Goto M, Izumi M, Naitoh M, Kurita K, et al. Anatomical considerations for the spread of odontogenic infection originating from the pericoronitis of impacted mandibular third molar: Computed tomographic analyses. *Oral Surg Oral Med Oral Pathol Oral Radiol Endod.* 2004;98(5):589-97.
  11. Qahash M, Susin C, Polimeni G, Hall J, Wikesjö UME. Bone healing dynamics at buccal peri-implant sites. *Clin Oral Implants Res.* 2008;19(2):166-72.
  12. Braut V, Bornstein MM, Lauber R, Buser D. Bone dimensions in the posterior mandible: a retrospective radiographic study using cone beam computed tomography. Part 1--analysis of dentate sites. *Int J Periodontics Restorative Dent.* 2012;32(2):175-84.
  13. Nowzari H, Molayem S, Chiu CHK, Rich SK. Cone beam computed tomographic measurement of maxillary central incisors to determine prevalence of facial alveolar bone width  $\geq 2$  mm. *Clin Implant Dent Relat Res.* 2012;14(4):595-602.
  14. Chen I, Karabucak B, Wang C, Wang Hg, Koyama E, Kohli Mr, et al. Healing after root-end microsurgery by using mineral trioxide aggregate and a new calcium silicate-based bioceramic material as root-end filling materials in dogs. *J Endod.* 2015;41(3):389-99.
  15. von Arx T, Janner SFM, Hänni S, Bornstein MM. Agreement between 2D and 3D radiographic outcome assessment one year after periapical surgery. *Int Endod J.* 2016;49(10):915-25.
  16. Wang X, Chen K, Wang S, Tiwari SK, Ye L, Peng L. Relationship between the mental foramen, mandibular canal, and the surgical access line of the mandibular posterior teeth: A Cone-beam Computed Tomographic Analysis. *J Endod.* 2017;43(8):1262-6.
  17. Zahedi S, Mostafavi M, Lotfirikan N. Anatomic study of mandibular posterior teeth using cone-beam computed tomography for endodontic surgery. *J Endod.* 2018;44(5):738-43.
  18. Kim D, Ha JH, Jin MU, Kim YK, Kim SK. Proximity of the mandibular molar root apex from the buccal bone surface: a cone-beam computed tomographic study. *Restor Dent Endod.* 2016;41(3):182-8.
  19. Jin G-C, Kim KD, Roh BD, Lee CY, Lee SJ. Buccal bone plate thickness of the Asian people. *J Endod.* 2005;31(6):430-4.
  20. Uğur Aydın Z, Göller Bulut D. Relationship between the anatomic structures and mandibular posterior teeth for endodontic surgery in a Turkish population: a cone-beam computed tomographic analysis. *Clin Oral Investig.* 2019;23(9):3637-44.
  21. Jhaveri HM, Amberkar S, Galav L, Deshmukh VL, Aggarwal S. Management of mucosal fenestrations by interdisciplinary approach: A Report of Three Cases. *J Endod.* 2010;36(1):164-8.
  22. Jorgić-Srdjak K, Plančak D, Bosnjak A, Azinović Z. Incidence and distribution of dehiscences and fenestrations on human skulls. *Coll Antropol.* 1999;22 Suppl:111-6.
  23. Edel A. Alveolar bone fenestrations and dehiscences in dry Bedouin jaws. *J Clin Periodontol.* 1981;8(6):491-99.
  24. Davies RM, Downer MC, Hull PS, Lennon MA. Alveolar defects in human skulls. *J Clin Periodontol.* 1974;1(2):107-11.
  25. Abdelmalek RG, Bissada NF. Incidence and distribution of alveolar bony dehiscence and fenestration in dry human Egyptian jaws. *J Periodontol.* 1973;44(9):586-8.
  26. Nimigean VR, Nimigean V, Bencze MA, Dimcevici-Poesina N, Cergan R, Moraru S. Alveolar bone dehiscences and fenestrations: an anatomical study and review. *Romanian J Morphol Embryol Rev Roum Morphol Embryol.* 2009;50(3):391-7.
  27. Larato DC. Alveolar plate fenestrations and dehiscences of the human skull. *Oral Surg Oral Med Oral Pathol.* 1970;29(6):816-9
- (Received April 3, 2021; Accepted July 16, 2021)