

Effects of Maxillary Protraction with Skeletal Anchorage and Petit-Type Facemask in High-Angle Class III Patients: A Retrospective Study

BURAK KALE¹, MUHAMMED HILMI BUYUKCAVUS²



ABSTRACT

Introduction: Skeletal anchorage-supported applications are performed to increase the skeletal effect of maxillary protraction used in the treatment of Class III malocclusions related to maxillary retrognathia.

Aim: To assess the craniofacial and soft tissue effects of the maxillary protraction with skeletal anchorage and Petit-type facemask in high-angle growth Class III young adolescent patients due to maxillary retrognathia.

Materials and Methods: The archives for this retrospective study were scanned according to inclusion criteria as follows: skeletal Class III malocclusion due to maxillary retrognathia, high-angle growth pattern, treated using face mask with miniplate anchorage. This study consisted of 15 patients (7 females and 8 males; mean age, 11.96±1.03 years) treated using Petit-type face mask with miniplate anchorage inserted in maxillae. Face-mask was used with an approximately 500 g force applied bilaterally from the hooks of the mini plates. Patients used Petit-type face mask for a total of 6 months for the first three months throughout the day, the next 3 months

for 12 hours a day. Cephalometric measurements were made to evaluate the effects of the maxillary protraction. The paired t-test was applied to evaluate differences between pre- and posttreatment variables.

Results: In our study, the skeletal Class III relationships were improved; maxillary measurements significantly increased (SNA° 3.48±0.42°; A-VRL 3.94±0.81 mm), SNB° decreased (-0.50±0.30°), ANB° increased (3.85±0.46°) (p<0.001) and SN-GoGn° slightly increased (0.25±0.21°) (p>0.05). The maxillary and mandibular incisors showed retroclination (-3.12±0.42° p<0.01; -0.46±0.24°; respectively). The changes in skeletal and dental parameters caused a significant increase in overjet (3.56±1.01 mm; p<0.001).

Conclusion: Using skeletal anchorage with Petit-type facemask has been successfully treated in patients with high-angle Class III young adolescent patients that provided an average increase in maxillary skeletal and soft tissue structures of 3.9 mm and undesired effects of conventional face mask treatment on vertical dimensional measurements were reduced.

Keywords: Miniplates, Maxillary retrognathia, Vertical growth pattern

INTRODUCTION

Class III anomalies are among the problems that are more difficult to treat in orthodontic malocclusions [1]. In the current day and age, patients with Class III malocclusion are more conscious of the visible effects on the facial appearance [2,3], due to their unfavourable effects on the psychosocial status of the patients. Components of Class III malocclusions are mandibular prognathism, maxillary retrognathism, or a combination of these two conditions [1].

Orthognathic surgery or camouflage treatment in adult patients and orthopedic treatments are preferred in young adolescents during growth and developmental period. Maxillary protraction treatment, which is frequently used in the treatment of skeletal Class III malocclusions related to maxillary retrognathism, also has undesirable effects [4].

In tooth-assisted maxillary protraction applications, undesirable dental effects develop as a consequence of protruding of the incisors along with the skeletal movement of the maxilla and increasing the vertical direction parameters as a result of extrusion of the maxillary molars. Due to the extrusion of the molar teeth, the clockwise rotation in the mandible, the counter-clockwise rotation in the maxilla causes an increase in the measurements in the vertical dimension of the patient [5,6]. Especially in patients with a high-angle growth pattern, if the need for maxillary protrusion is increased compared to patients with normal growth patterns, such maxillary protraction applications may reduce overbite and increase the vertical dimensional measurements [7].

Various methods are applied in Class III patients with high-angle growth pattern in order not to increase vertical dimension more. In the literature, it is recommended to use Nanda-type [8] and Grummons-type [9] face masks in order not to increase the vertical direction dimensions for this type of patient. Also, skeletal anchorage methods [10,11], which enable us to apply force over the center of the resistance, are also used successfully.

This study aimed to assess the craniofacial and soft tissue effects of the maxillary protraction with skeletal anchorage along with Petit-type facemask when used for the treatment of high-angle Class III young adolescent patients due to maxillary retrognathia.

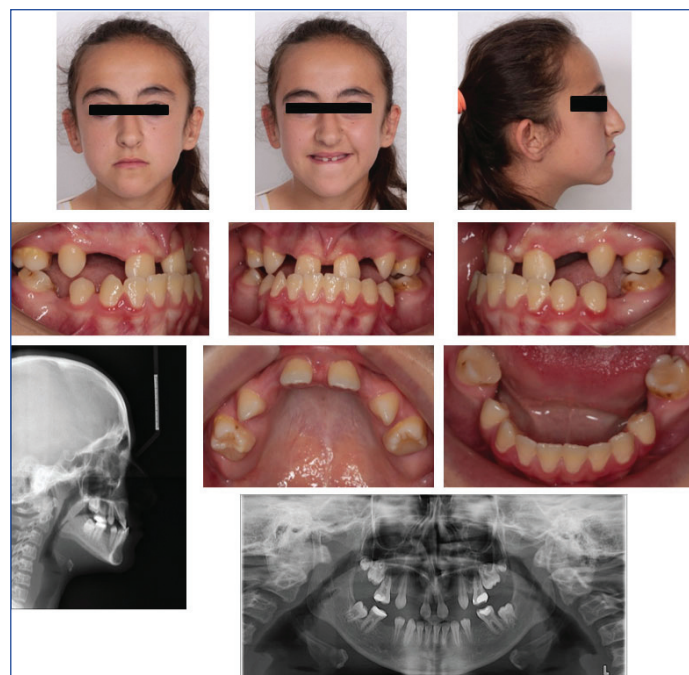MATERIALS AND METHODS

A retrospective study of patients with high angle growth pattern Class III malocclusions treated with maxillary protraction skeletal anchorage between June 2018 and June 2019 years in Suleyman Demirel University, Orthodontic Department of Dentistry. Ethical approval of this retrospective study was obtained from Clinical Research Ethics Committee of Süleyman Demirel University Faculty of Medicine (Ethics approval decision number: 28.05.2019/190) and parents of the patients had signed an informed consent form allowing the authors to use their data (images, cephalograms, etc..) for scientific purposes. The sample size was calculated based on a significance level of 0.05 and a power of 80%. It was determined that 15 patients were required by performing power analysis.

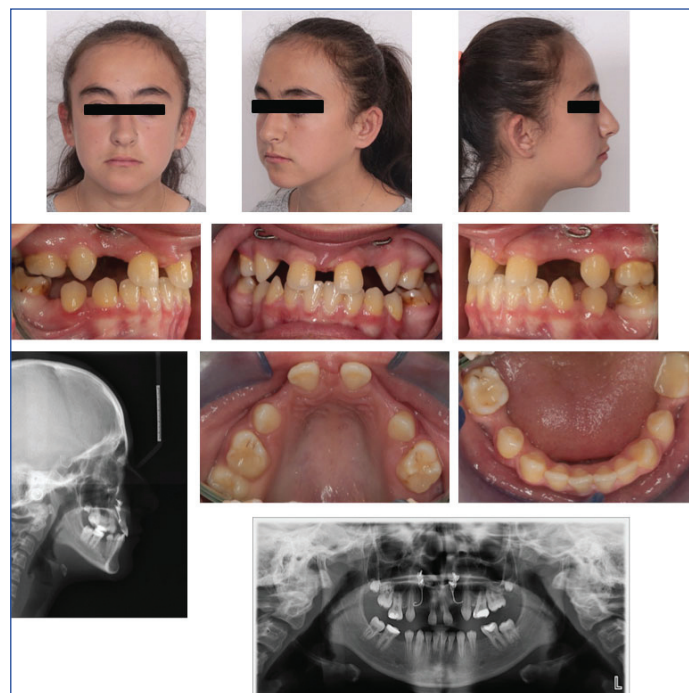
One of two authors regularly scanned the archives to determine the study samples according to inclusion criteria as follows: [1] skeletal and dental Class III malocclusion due to maxillary retrognathia ($\text{SNA} < 80^\circ$ and $\text{ANB} < 0^\circ$); [2] high-angle growth pattern ($\text{SN-GoGn} > 38^\circ$); [3] treated using face mask with miniplate anchorage inserted in the lateral nasal wall; [4] no extraction except third molars; [5] no systemic disease and congenital anomalies.

A total of 23 patients selected from the archives were evaluated in terms of the application of face mask and vertical direction measurements. 15 patients with inclusion criteria were identified. Six patients were excluded because of different maxillary protraction, and 2 patients were excluded from the study due to inadequate records. According to the cervical vertebral maturation method, all patients were in the prepubertal and pubertal stage of skeletal maturity (Stage 1-4). This study consisted of 15 patients (7 females and 8 males; mean age, 11.96 ± 1.03 years) treated using face mask with miniplate anchorage inserted in below the Apertura piriformis region. Maxillary protraction was applied by placing two I shaped titanium mini plates (Stryker, Leibinger, GmbH and Co KG, Freiburg, Germany). A mucoperiosteal flap was made and elevated from maxillary lateral incisor and canines to the lateral nasal wall on both sides under local anesthesia. At this stage, more attention has been paid to avoid harming canine teeth. Titanium mini plates were modified according to the Apertura piriformis anatomic structures and then placed with 3 monocortical mini-screws (diameter, 1.5 mm; length, 7 mm). After 1 week for soft-tissue healing, protraction forces were applied with 5/16 medium pull elastics immediately. Force levels measured by a dynamometer (Correx 0-250 g, Bern, Switzerland).

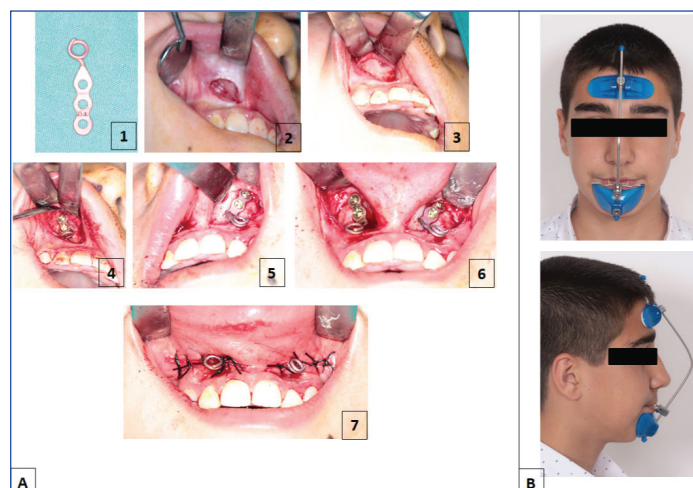
Petit-type face-mask was used with an approximately 500 g bilateral same force applied with an anteroinferior force vector of approximately 30° to the occlusal plane from the hooks of the mini plates. Patients used a total of 6 months' Petit-type face mask for the first three months throughout the day (approximately, 18-20 hours in a day), the next 3 months for 12 hours a day [Table/Fig-1-3]. The duration of treatment of the patients is 7 months on average (0.61 ± 0.21 years).



[Table/Fig-2]: Pretreatment intraoral, extraoral photos lateral cephalogram and orthopantomogram radiographs in Class III malocclusion patient with maxillary retrognathia, negative overjet.

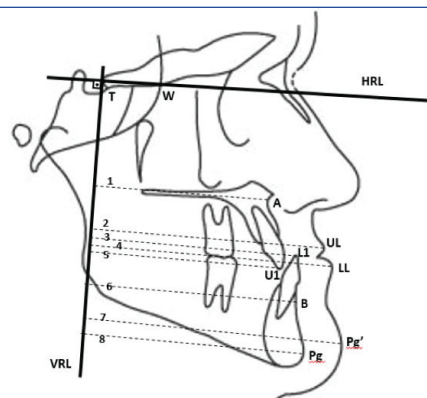


[Table/Fig-3]: Post protraction intraoral, extraoral photos lateral cephalogram and orthopantomogram radiographs in Class III malocclusion patient with improved facial profile and dental malocclusion with positive overjet.



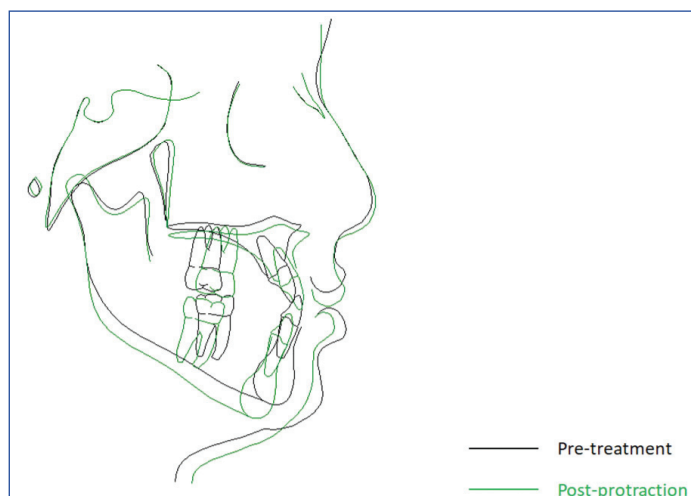
[Table/Fig-1]: Miniplates and surgical placement of miniplates: a- 1) I shaped titanium; 2, 3) a mucoperiosteal flap elevated; 4) miniplate placed; 5) miniplate secured with mini-screws; 6) 2 mini plates placed; 7) sutures placed along with hooks for elastics and B) Petit type Face-Mask used in the study.

Cephalograms were taken (Planmeca Promax, Planmeca Co., Ltd., Helsinki, Finland) at the beginning (T1) and after 6 months maxillary protraction therapy (T2). An imaginary line which passes via tuberculum sella and wing point (junction of the contour of the ala major with jugum sphenoidale) was used as the Horizontal Reference Line (HRL) and a line perpendicular through tuberculum sella as a Vertical Reference Line (VRL) [Table/Fig-4].

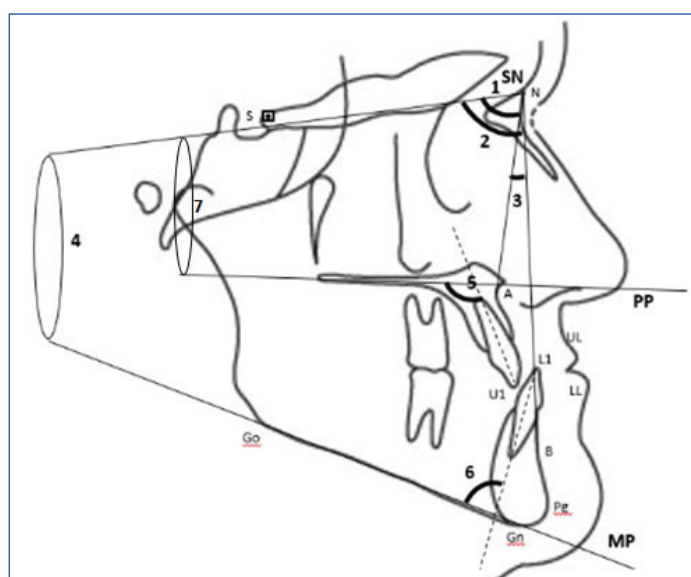


[Table/Fig-4]: Reference planes used in the study and linear measurements according to reference planes: (1) A-VRL; (2) UL-VRL; (3) L1-VRL; (4) LL-VRL; (5) U1-VRL; (6) B-VRL; (7) Pg'-VRL; (8) Pg-VRL.

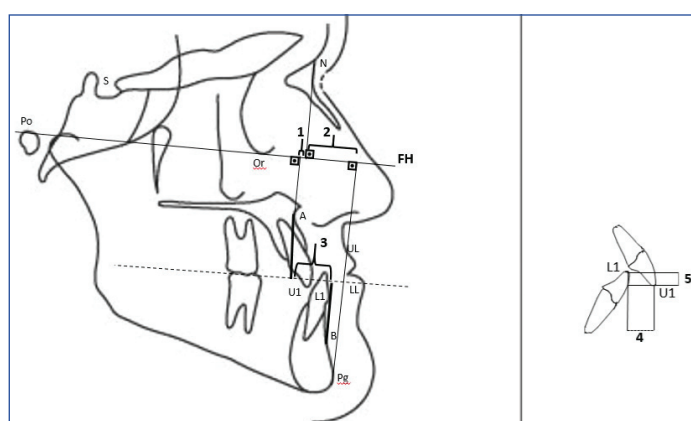
After calibration, all radiographs were traced blindly by a single researcher [Table/Fig-4-7]. (Steiner, Tweed, Wits and McNamara Analysis was used, measurements were also made based on the reference planes) were made to evaluate and compare the craniofacial and soft tissue effects of the maxillary protraction using Dolphin Imaging Version 11.8.06.24 Premium software (Dolphin Imaging and Management Solutions, Chatsworth Calif).



[Table/Fig-5]: Superimpositions of cephalometric tracings (Cranial Base (Sella/Nasion) for overall change during treatment).



[Table/Fig-6]: Cephalometric angular measurements: (1) SNA°; (2) SNB°; (3) ANB°; (4) SN-GoGn°; (5) U1-PP°; (6) IMPA°; (7) SN-PP°



[Table/Fig-7]: Cephalometric linear measurements: (1) NPerp-A (mm); (2) NPerp-Pg (mm); (3) Wits (mm); (4) Overjet (mm); (5) Overbite (mm)

STATISTICAL ANALYSIS

All statistical analyses were performed using the SPSS software package program (SPSS for Win, ver 21.0; SPSS Inc., Chicago, Ill)

for all tests. Eight radiographs were selected randomly 15 days after the first evaluation, and all measurements were performed again by the same researcher. The method error was detected using the Houston test [12]. It was observed that the coefficient of reliability for all of our measurements was high (highest value SNA° 0.998, A-VRL 0.975; the lowest value SNB° 0.876).

The parametric tests were used for statistical evaluation since the Shapiro-Wilks test showed normally distributed variables. The paired t-test was applied to evaluate differences between pre-(T1) and post-(T2) treatment variables. The significance level was set at $p < 0.05$.

RESULTS

The descriptive data, including chronological age, the gender distribution is shown in [Table/Fig-8]. The mean chronological age was 11.96 ± 1.03 years. The mean duration of treatment was 0.61 ± 0.21 years. The initial cephalometric values of the patients are shown in [Table/Fig-8]. The patients had skeletal Class III malocclusion due to the maxillary retrognathism, high-angle growth pattern, proclined upper incisors, and retroclined lower incisors. Changes occurred during maxillary protraction; the statistical comparison of these changes is shown in [Table/Fig-8]. The total superimposition of cephalometric tracings of one of the patients in our study is shown in [Table/Fig-5].

In this study, the skeletal class III relationships and anterior crossbites were improved; maxillary measurements significantly increased (SNA° $3.48 \pm 0.42^\circ$; A-VRL 3.94 ± 0.81 mm; NPerp-A 3.84 ± 0.64 mm; $p < 0.001$), SNB° decreased ($-0.50 \pm 0.30^\circ$; $p > 0.05$), ANB° increased ($3.85 \pm 0.46^\circ$; $p < 0.001$) and SN-GoGn° slightly increased ($0.25 \pm 0.21^\circ$; $p > 0.05$) which resulted in 3.94 mm forward movement (A-VRL) and 0.19 degree clockwise rotation (SN-PP) in the maxilla and 0.25 degree rotation in the mandible (SN-GoGn) ($p < 0.001$).

In order to determine the amount of advancement of the maxilla, the vertical distance of point A to the VRL was examined, and the monthly advancement rate was determined by dividing the change after the protraction and the duration of treatment. As a result of an average of 7 months of protraction, the rate of maxillary advancement was determined as 0.53 mm per month.

The maxillary and mandibular incisors showed retroclination (-3.12 ± 0.42 $p < 0.01$; $-0.46 \pm 0.24^\circ$; respectively). The changes in skeletal and dental parameters caused a significant increase in overjet (3.56 ± 1.01 mm; $p < 0.001$) and decrease overbite (-0.35 ± 0.66 mm; $p > 0.05$) measurements. The upper lip moved forward (3.13 ± 0.74 mm; $p < 0.001$), and the lower lip (-0.66 ± 0.48 mm; $p > 0.05$) and soft tissue pogonion (-2.26 ± 1.03 mm; $p > 0.05$) moved backward.

After obtaining at least 2 mm positive overjet of patients and completing at least 6 months of maxillary protraction, fixed orthodontic treatments were initiated for patients who were in permanent dentition, and the mini plates remained in the mouth and continued to use face masks for retention at night. Mini plates were removed at the end of treatment.

DISCUSSION

For individuals with a high angle growth pattern, the growth rate of the jaw in the vertical direction is higher than in the normal growth pattern. If these individuals can not compensate for the growth in the vertical direction of the jaws, the open bite can occur [13]. If individuals with high-angle growth patterns have class III malocclusion due to maxillary retrognathism, the treatment becomes more complicated [7].

When the tooth-supported face mask used in Class III malocclusion therapy, there is an increase in the vertical direction measurements of the patients due to the extrusion of the maxillary molars and due to the clockwise rotation of the mandible [14-17]. Different methods are used for maxillary protraction in individuals with high-angle growth pattern. Grummons type [9] face mask which does not support the chin side to reduce the clockwise rotation of the

		Norm values	Pre treatment	Post protraction	Mean changes		
	Parameters	Mean±SD	Mean±SD	Mean±SD	Mean±SD	p	
	Demographic data						
	Chronological age (Years)		11.96±1.03	12.46±0.83	0.50±0.93		-
	Gender distribution (Female/Male)		7 Female/8 Male				-
Maxillary measurements	SNA (°)	82±2	76.56±0.79	80.04±0.61	3.48±0.42	0.000	***
	N Perp A (mm)	0±2	-4.66±2.74	-0.82±2.63	3.84±0.64	0.000	***
	CoA (mm)	85±5	80.19±0.74	84.95±0.69	4.76±0.41	0.000	***
	A-VRL (mm)	-	45.52±3.16	49.46±2.52	3.94±0.81	0.000	***
Mandibular measurements	SNB (°)	80±2	78.78±0.82	78.28±0.93	-0.50±0.30	0.132	NS
	N Perp Pg (mm)	-4±5	6.10±0.49	5.07±0.33	-1.03±0.50	0.027	*
	CoGn (mm)	112±5	116.57±0.46	117.31±0.29	0.74±0.21	0.352	NS
	B-VRL (mm)	-	44.84±2.79	43.99±2.71	-0.85±0.28	0.487	NS
	Pog-VRL (mm)	-	44.53±3.56	43.02±3.71	-1.51±0.50	0.698	NS
Vertical measurements	SN-GoGn (°)	32±6	38.98±1.01	39.23±1.03	0.25±0.21	0.741	NS
	PP-MP (°)	28±3	32.8±2.5	33.04±2.53	0.24±0.14	0.9258	NS
	SN-PP (°)	8±3	11.68±2.43	11.48±2.44	-0.19±1.33	0.018	*
	SN-Occ (°)	16±4	18.71±1.84	18.88±1.79	0.17±0.12	0.016	*
Maxillo- mandibular measurements	ANB (°)	2±2	-2.08±0.69	1.76±0.85	3.85±0.46	0.000	***
	Wits (mm)	1±1	-4.36±1.45	0.51±0.88	4.88±0.70	0.000	***
Dentoalveolar measurements	U1-PP (°)	110±5	129.44±4.22	126.31±4.41	-3.12±0.42	0.007	**
	IMPA (°)	90±5	87.16±2.62	86.70±2.70	-0.46±0.24	0.249	NS
	U1-VRL (mm)	-	118.06±5.02	116.46±4.70	-1.60±0.91	0.024	*
	L1-VRL (mm)	-	60.36±1.13	59.11±1.22	-1.24±0.82	0.367	NS
	Overjet (mm)	2±2	-1.44±0.99	2.12±1.07	3.56±1.01	0.000	***
	Overbite (mm)	2±2	0.76±1.49	0.41±1.45	-0.35±0.66	0.489	NS
Soft tissue measurements	Nasolabial angle	105±5	112.34±3.78	104.25±4.21	-8.09±0.99	0.000	***
	UL-S (mm)	0±2	-2.16±0.31	0.41±0.24	2.57±0.43	0.000	***
	LL-S (mm)	0±2	0.98±0.34	0.66±0.51	-0.32±0.44	0.007	**
	UL-VRL (mm)	-	61.06±4.31	64.20±3.91	3.13±0.74	0.000	***
	LL-VRL (mm)	-	63.20±4.61	62.53±4.61	-0.66±0.48	0.159	NS
	Pog(s)-VRL (mm)	-	61.20±4.07	58.93±4.31	-2.26±1.03	0.365	NS

[Table/Fig-8]: Demographic datas, initial cephalometric values for study subjects and statistical evaluations of changes obtained in maxillary protraction.

P: Results of paired t-test; SD: Standard deviation. *p<0.05; **p<0.01; ***p<0.001; NS: Not significant p>0.05

mandible, Nanda-type, Grummons-type [8] face mask which has the possibility of applying force over the resistance center of the maxilla, and skeletal anchorage supported face mask which can apply force in front of the resistance center of maxilla [10,11].

Many researchers have defined the center of resistance of maxillae [18-22]. When the protraction force is applied over the center of resistance of the maxillary, the counterclockwise rotation of the maxillary descends to a minimum and is prevented in the complications that occur in the vertical direction. Similar to this study in the literature, skeletal anchorage assisted maxillary protraction applications are available [10,11,23]. However, the difference in the current study is that there is no intraoral unit (Rapid Maxillary Expansion (RME) etc.,) within the mouth. With this application, pure skeletal protraction was made without support from the teeth. Thus, the extrusion in the posterior teeth associated with the expansion is prevented and therefore vertical measurements are minimised.

When the changes caused by the treatment were evaluated, it was found that the maxilla moves forward 3.9 mm. In similar studies Kircelli BH and Pektas ZO detected the maxilla moves forward 4.82 mm as a result of a face-mask for 10 months, Sar C et al., moved forward 3.11 mm in 7 months, and Elnagar MH et al., 4.87 mm in 8 months [10,24,25]. As a result, an increase was observed in the maxillary measurements. The face mask showed a reduction in mandibular measurements supported by chin and improvement in maxillomandibular measurements. Retrusions were seen in the lower incisors due to the chin part of the face mask and in

the upper incisors due to the change of the inclination of the palatal plane due to the application of force in front of the resistance center of the maxilla. Overjet has been improved due to both maxillary and mandibular changes. The increase in vertical measurement and the decrease in overbite were minimised because of the skeletal anchorage support during the protraction and because there was no intraoral unit supported the teeth. When soft tissue measurements were evaluated, significant improvement was also observed in the soft tissue profile of the patients, with the upper lip moving forward and lower lip moving backward.

Approximately, 3.12° retrusion in the palatal plane angle with upper incisor was observed in the treatment period this can be explained by the increasing lip pressure on the maxillary incisors after eliminating the anterior crossbite.

The rotational direction of the mandible in posterior direction and an increase in the mandibular plane was observed as an increase of 0.25 degrees (p>0.05), thus there was no significant effect on the mandible. The researchers Sar C, Kircelli BH, Elnagar MH found increases in the SN/GoGn angle of 1.2, 1.29 and 2.03 degrees. A minimal decrease of 0.19 degrees was detected in the slope of the palatal plane [10,11,24,25]. The reason for the low vertical increase in this study may be due to the pure skeletal effect and the absence of a device such as RME etc., in the mouth. The side effects in the tooth-borne anchorage caused by traditional maxillary protraction were avoided with the method used in the current study. As for the use of Apertura piriformis region anchorage, the inability to place

mini plates in the owing to limited space in patients and the 2-step local surgery involved placement and removal of miniplates are considered to be the clinical disadvantages of this method. RME, which is frequently used in the treatment of Class III malocclusion with face mask, is known to affect the circummaxillary sutures and forward movement of the maxilla [25-28]. In this study, A point was displaced only due to the forward movement of the maxilla without any movement in any point due to RME. In a study Sar C et al., applied RME and mini plates with face mask in growing patients. Maxillary protraction rates with RME and skeletal anchorage was 0.45 mm [10]; Elnagar MH et al., 0.59 mm/month [25]. In this study Point A moved 0.53 mm/month.

Limitation(s)

The clinical studies should include the control group to differentiate the treatment applied from the changes that occur with growth and development. It is not ethical to keep these Class III patients to create a control group without treating them [29]. The control group was not included in the study due to medical ethics.

After the retention and long-term results of the studies, it attracts more attention of the readers and makes the study more valuable. As this study was retrospective and the selection was made from the archive, all patients could not be reached for long-term follow-up. This method requires long-term study and results to determine the amount of relapse and recurrence.

Future studies can be compared both in terms of different maxillary protraction methods and different anchorage units treatment effectiveness. In addition, relapse amounts can be revealed by comparing long term results in terms of relapse.

CONCLUSION(S)

The method of skeletal anchorage with Petit-type facemask is one of the alternative treatment methods in patients with high angle Class III young adolescent patients. Approximately, 3.9 mm forward movement is observed in the maxilla, while rotational movements in both the maxilla and the mandible are minimised.

This method has minimised vertical dimensional measurements and undesirable dentoalveolar effects due to a lack of support from the teeth. Negative overjet was corrected skeletally by the maxillary advancement rather than dentoalveolar correction.

REFERENCES

- [1] Litton SF, Ackerman LV, Isaacson J, Shapiro BL. A genetic study of Class III malocclusion. *Am J Orthod.* 1970;58:565-77.
- [2] Irie M, Nakamura S. Orthopedic approach to severe skeletal Class III malocclusion. *Am J Orthod.* 1975;67:377-92.
- [3] Celikoglu M, Akpinar S, Yavuz I. The pattern of malocclusions in a sample of orthodontic patients from Turkey. *Med Oral Patol Oral Cir Bucal.* 2010;15:e791-96.
- [4] Mermigos J, Full CA, Andreasen G. Protraction of Maxillofacial complex. *Am J Dentofac Orthod.* 1990;98:47-55.
- [5] Gallagher RW, Miranda F, Buschang PH. Maxillary protraction: Treatment and posttreatment effects. *Am J Orthod Dentofacial Orthop.* 1998;113:612-19.
- [6] Macdonald KE, Kapust AJ, Turley PK. Cephalometric changes after the correction of class III malocclusion with maxillary expansion/facemask therapy. *Am J Orthod Dentofacial Orthop.* 1999;116:13-24.
- [7] Proffit WR, Fields HW, Sarver DM. *Contemporary Orthodontics.* 4th Ed. St. Louis: Mosby Elsevier. 2007;P:268-327.
- [8] Nanda R, Goldin B. Biomechanical approaches to the study of alterations of facial morphology. *Am J Orthod Dentofacial Orthop.* 1980;78:213-26.
- [9] Hegmann M, Rüther AK. The Grummons face mask as an early treatment modality within a Class III therapy concept. *Journal of Orofacial Orthopedics/ Fortschritte der Kieferorthopädie.* 2003;64(6):450-56.
- [10] Sar C, Sahinoğlu Z, Özçirpici AA, Uçkan S. Dentofacial effects of skeletal anchored treatment modalities for the correction of maxillary retrognathia. *Am J Orthod Dentofacial Orthop.* 2014;145(1):41-54.
- [11] Sar C, Arman-Ozçirpici A, Uçkan S, Yazici AC. Comparative evaluation of maxillary protraction with or without skeletal anchorage. *Am J Orthod Dentofacial Orthop.* 2011;139:636-49.
- [12] Houston WJ. The analysis of errors in orthodontic measurements. *Am J Orthod.* 1983;83(5):382-90.
- [13] Kale B, Buyukcavus MH. Pure skeletal maxillary protraction with skeletal anchorage in high-angle Class III patients: A case series. *Journal of the World Federation of Orthodontists.* 2018;7(2):66-78.
- [14] Arat ZM, Türkahraman H, English JD, Gallerano RL, Boley JC. Longitudinal growth changes of the cranial base from puberty to adulthood: A comparison of different superimposition methods. *Angle Orthod.* 2010;80(4):725-32.
- [15] Celikoglu M, Buyukcavus MH. Changes in pharyngeal airway dimensions and hyoid bone position after maxillary protraction with different alternate rapid maxillary expansion and construction protocols: A prospective clinical study. *Angle Orthod.* 2017;87(4):519-25.
- [16] Baccetti T, Franchi L, McNamara JA. Treatment and posttreatment craniofacial changes after rapid maxillary expansion and facemask therapy. *Am J Orthod Dentofacial Orthop.* 2000;118:404-13.
- [17] Yu HS, Baik HS, Sung SJ, Kim KD, Cho YS. Three-dimensional finite element analysis of maxillary protraction with and without rapid palatal expansion. *Eur J Orthod.* 2007;29:118-25.
- [18] Baccetti T, Franchi L, McNamara JA Jr. Growth in the untreated Class III Subject. *Semin Orthod.* 2007;13:130-42.
- [19] Ngan P, Hagg U, Yiu C, Merwin D, Wei SH. Soft tissue and dentoalveolar profile changes associated with maxillary expansion and protraction headgear treatment. *American Journal of Orthodontics and Dentofacial Orthopedics.* 1996;109:38-49.
- [20] Tanne K, Miyasaka J, Yamagata Y, Sachdeva R, Tsutsumi S, Sakuda M. Three-dimensional model of human craniofacial skeleton: Method and preliminary results using finite elements analysis. *J Biomed Eng.* 1988;10:246-52.
- [21] Staggers JA, Germane N, Legan HL. Clinical considerations in the use of protraction headgear. *J Clin Orthod.* 1992;26:87-91.
- [22] Miki M. An experimental research on the directional control of the nasomaxillary complex by means of external force- Two dimensional analysis on the sagittal plane of the craniofacial skeleton. *Shikwa Gakuho.* 1979;79:1563-97.
- [23] Hata S, Itoh T, Nakagawa M, Kamogashira K, Ichikawa K, Matsumoto M, et al. Biomechanical effects of maxillary protraction on the craniofacial complex. *Am J Orthod Dentofacial Orthop.* 1987;91:305-11.
- [24] Kircelli BH, Pektas ZÖ. Midfacial protraction with skeletally anchored face mask therapy: A novel approach and preliminary results. *Am J Orthod Dentofacial Orthop.* 2008;133(3):440-49.
- [25] Elnagar MH, Elshourbagy E, Ghobashy S, Khedr M, Evans CA. Comparative evaluation of 2 skeletally anchored maxillary protraction protocols. *Am J Orthod Dentofacial Orthop.* 2016;751-62.
- [26] McNamara JA. An orthopedic approach to the treatment of Class III malocclusion in young patients. *J Clin Orthod.* 1987;21:598-608.
- [27] Turley PK. Orthopedic correction of Class III malocclusion with palatal expansion and custom protraction headgear. *J Clin Orthod.* 1988;22:314-25.
- [28] Haas J. Rapid expansion of the maxillary dental arch and nasal cavity by opening the mid-palatal suture. *Angle Orthod.* 1961;31:73-90.
- [29] Papadopoulos MA. Meta-analyses and orthodontic evidence-based clinical practice in the 21st century. *Open Dent J.* 2010;4:92-123.

PARTICULARS OF CONTRIBUTORS:

1. Assistant Professor, Department of Orthodontics, Antalya Bilim University, Antalya, Turkey.
2. Assistant Professor, Department of Orthodontics, Suleyman Demirel University, Isparta, Turkey.

NAME, ADDRESS, E-MAIL ID OF THE CORRESPONDING AUTHOR:

Muhammed Hilmi Buyukcavus,
Assistant Professor, Department of Orthodontics, Suleyman Demirel University,
Isparta, Turkey.
E-mail: mhbuyukcvs@gmail.com

AUTHOR DECLARATION:

- Financial or Other Competing Interests: None
- Was Ethics Committee Approval obtained for this study? Yes
- Was informed consent obtained from the subjects involved in the study? Yes
- For any images presented appropriate consent has been obtained from the subjects. Yes

PLAGIARISM CHECKING METHODS: [Jain H et al.]

- Plagiarism X-checker: Dec 13, 2019
- Manual Googling: Feb 07, 2020
- iThenticate Software: Feb 26, 2020 (18%)

ETYMOLOGY: Author Origin

Date of Submission: Dec 12, 2019
Date of Peer Review: Jan 23, 2020
Date of Acceptance: Feb 07, 2020
Date of Publishing: Mar 01, 2020

Copyright of Journal of Clinical & Diagnostic Research is the property of JCDR Research & Publications Private Limited and its content may not be copied or emailed to multiple sites or posted to a listserv without the copyright holder's express written permission. However, users may print, download, or email articles for individual use.